

ESWT for adult Osteochondrosis dissecans
S. Marx, Ch. Herbert, R. Thiele
IZS Berlin, International Center for Shockwave
presented at the EFORT congress - Helsinki 03

Introduction:

Aim of this study is to show the use of ESWT for adult osteochondrosis dissecans of the femur condyle and talus as a causal therapy.

Osteochondrosis dissecans:

The Osteochondrosis dissecans is described as a localized aseptic bone necrosis that undergoes a development from a sclerotic area to a defect of the articular surface.

The Osteochondrosis dissecans can as well be described as a local pseudarthrotical reaction of the tissue, that leads to a local chondral destruction and the formation of a loose body.

Based on this statement and the good results of ESWT on non-unions the idea of treating the OD by ESWT was born.

Etiology of Osteochondrosis dissecans:

The etiology remains unclear but mainly mechanical factors, a vascularization failure and traumatic injuries are discussed.

The juvenile Osteochondrosis dissecans has to be divided from the adult form as far as a spontaneous healing process can be seen in over 70% of the juvenile forms.

The Osteochondrosis dissecans shows an increased incidence for athletes.

Pathogenesis of Osteochondrosis dissecans:

The illness undergoes four stades. The initial stadium shows a subchondral osteonecrosis followed by sclerosis and demarcation with a zone of condensation next to the affected area. This leads in the end to a substantial defect with the formation of an intraarticular loose body, called the Dissecat in situ.

The affected area is located in.

As a chronic longterm disease the Osteochondrosis dissecans is stated as a pre-arthrosis.

Classification of Berndt & Harty

- Grade I: In situ bone fragment without evidence of displacement
- Grade II: In situ bone fragment without migration but irregular cartilaginous fragment
- Grade III: In situ bone fragment with migrated cartilaginous fragment
- Grade IV: Migrated bone and cartilage fragment

ESWT for adult Osteochondrosis dissecans
S. Marx, Ch. Herbert, R. Thiele
IZS Berlin, International Center for Shockwave

Therapeutics of osteochondrosis dissecans at the time:

At the moment there are only conservative treatment and surgical intervention.

The conservative treatment supports the spontaneous healing process by immobilisation and reduction of physical strain for weeks and can be accompanied by an analgetic therapy.

Surgical intervention shows a more complex range of possibilities. Being more or less invasive the aim is to get a revitalisation of the affected area by retrograd and anterograd drilling, subchondralspongiosa-plasty, bone-cartilage-transplantation and in case of a Dissecat-in-Situ the refixation.

Main aim of every therapeutical strategy is to reach a revitalization of the osteochondrotical region and the prevention of progression and arthrosis.

The patient would benefit of a treatment with ESWT as this is a minimal invasive treatment without severe complications.

But of course this is still experimental and the working mechanisms of shockwave therapy are still not solved.

Treatment-Protocol:

ESWT was performed with the Ossatron by HMT.

2400 Impulses at 0.35 mJ/mm² were applied in general or field anaesthesia.

The patient had to relief the affected joint for 2 to 6 weeks after treatment alternatively by the use of a Mecron-Orthesis.

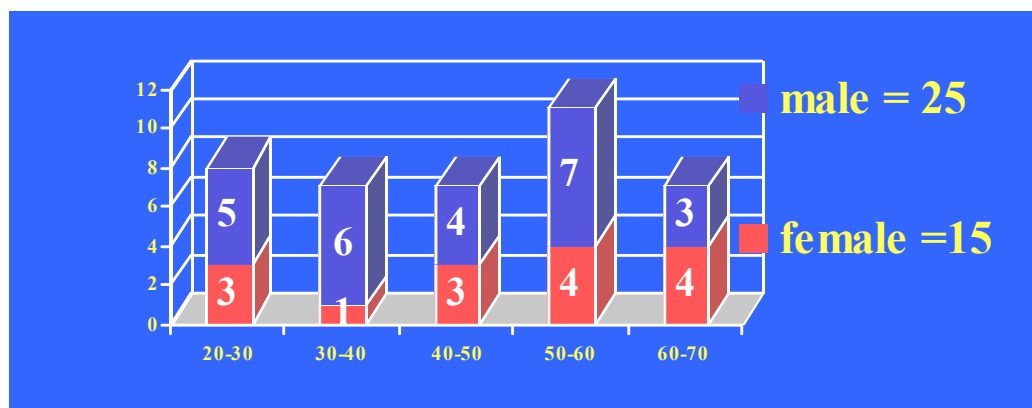
The patients were evaluated by a

- VAS, ranging from 0 to 10
- a subjective score,
- the Score by Larson and the Score by Brückl for the knee-joint
- and the Score by Mazur for the ankle-joint.

The follow up was performed before the treatment, 6 weeks and 3, 6 and 12 months after treatment.

Study-Protocol:

Evaluated in this study are 40 patients, 25 male and 15 female. All patients showed an OD I-II°
29 times the knee was treated and 11 times the ankle-joint.



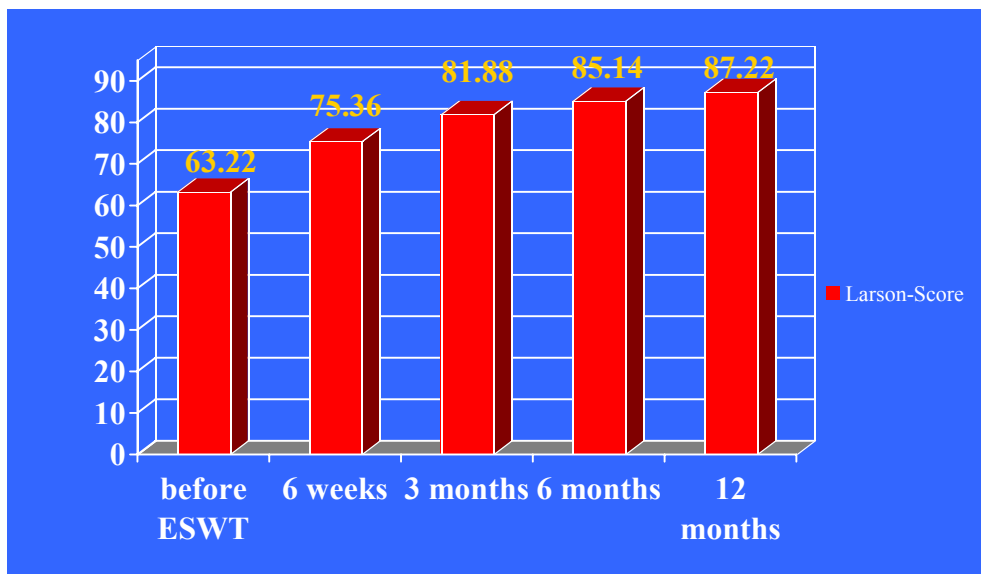
ESWT for adult Osteochondrosis dissecans
S. Marx, Ch. Herbert, R. Thiele
IZS Berlin, International Center for Shockwave

Results:

The Larson-Score for the knee-joint shows a development from 63.22 points over all treated knees before ESWT to 87.22 a year after ESWT.

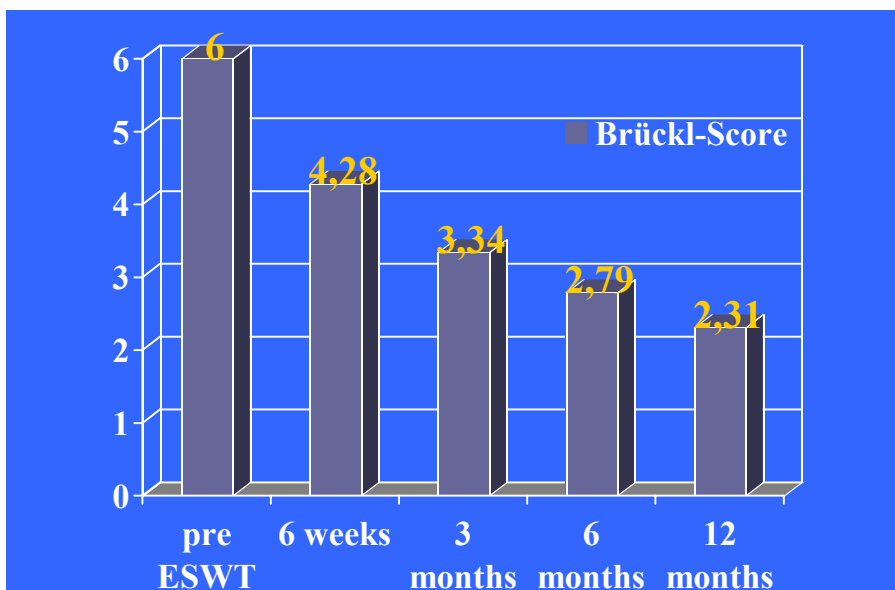
This shows a highly significant increase ($p < 0.001$, $\Sigma^2 = 0.733$) over the whole period and in between the controlled time periods.

The gender and the affected side show no relevance on the outcome.



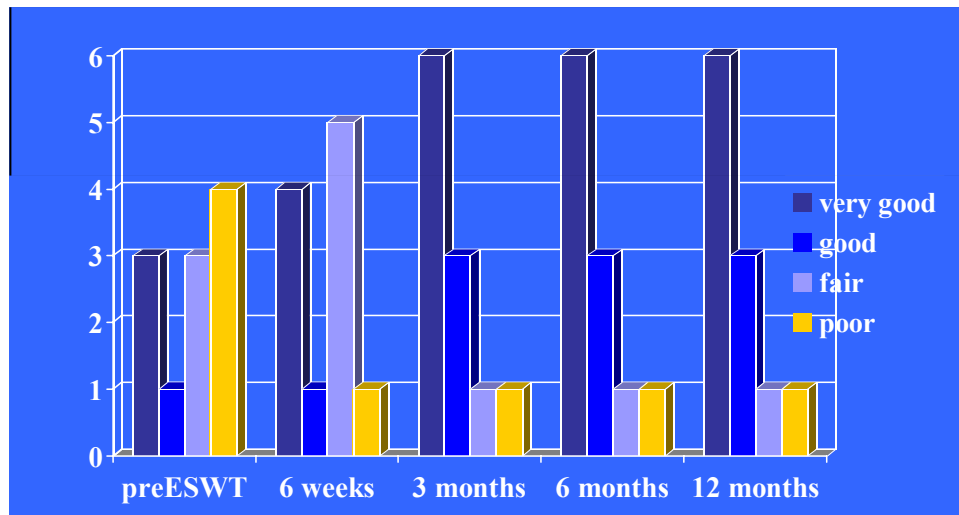
Correlating to the Larson-Score the Brückl-Score decreased from 6 points before treatment to 2.31 points a year after treatment.

This stands for a highly significant change ($p < 0.001$, $\Sigma^2 = 0.717$).

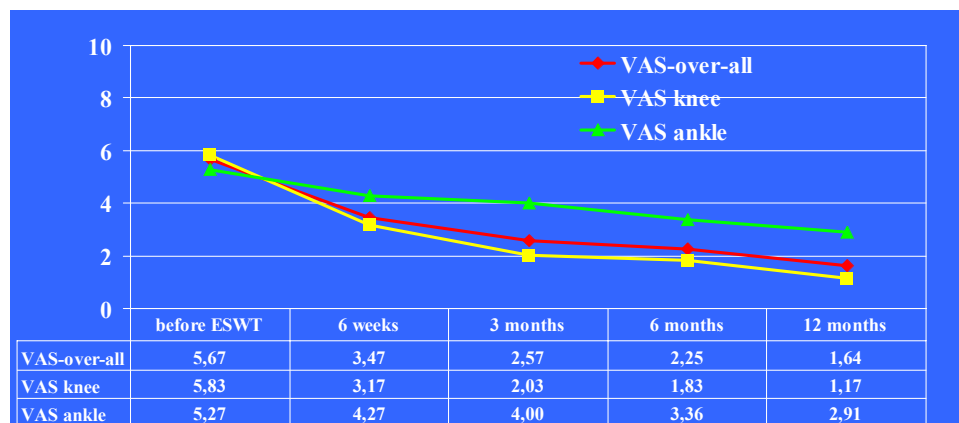


ESWT for adult Osteochondrosis dissecans
S. Marx, Ch. Herbert, R. Thiele
IZS Berlin, International Center for Shockwave

The Mazur-Score for the ankle-joint shows an increase of good and very good results. The results over the period of one year are significant ($p < 0.001$, $\Sigma^2 = 0.554$) and show the highest increase in the periods of 2 to 6 weeks, 6 weeks to 3 months and 3 months to 6 months.



The VAS has to be distinguished in between the knee-joint and the ankle-joint.



For the knee-joint the changes in the evaluated time period are highly significant ($p < 0.001$, $\Sigma^2 = 0.746$) and gender and affected side show no relation to the outcome.

Even the changes from one controlling evaluation to the next show significant results.

The biggest change in the VAS can be shown in the period of 2 weeks to 6 weeks and 6 weeks to 3 months.

For the ankle-joint the results of the VAS are significant ($p = 0.006$, $\Sigma^2 = 0.422$) and show the highest change in the period of 3 months to 6 months.

While 60% of the patients suffered from bad pain in rest and soft exercises the patients had no bad pain after the treatment and only in 38% a little pain doing hard exercises.

Nobody showed pain while rest after the treatment.

Before the treatment 62% suffered from swelling of the joint, after the treatment only 13% showed signs of swelling.

Over 72% of the patients had pain doing the daily life, after the one year follow-up only 27% showed little pain during daily living and only 10% bad pain doing hard exercises.

ESWT for adult Osteochondrosis dissecans
S. Marx, Ch. Herbert, R. Thiele
IZS Berlin, International Center for Shockwave

Discussion:

The knee-joint shows better results than the ankle-joint which seems to correlate with the difficulties to reach the affected area of the ankle-joint. While reaching the OD of the knee-joint shows no complications the ankle-joint with less mobility can not be reached in every case.

Conclusion:

In Conclusion and thanks to the results of the Statisticians we want to point out the following statements:

The ESWT for the adult Osteochondrosis dissecans shows to be effective
The OD of the talus still shows difficulties to be reached and therefore should only be treated with ESWT if the location shows to be reachable
The ESWT is a treatment with minimal stress and risk for the patient
ESWT seems to be an alternative to the surgical treatments that are in use at the time

Case-Report:

The pictures show the development of a 38 year-old male.
The patient suffered from bad pain. A trauma was not reported.
As the MRI shows the affected area shows a continuously positive course.

