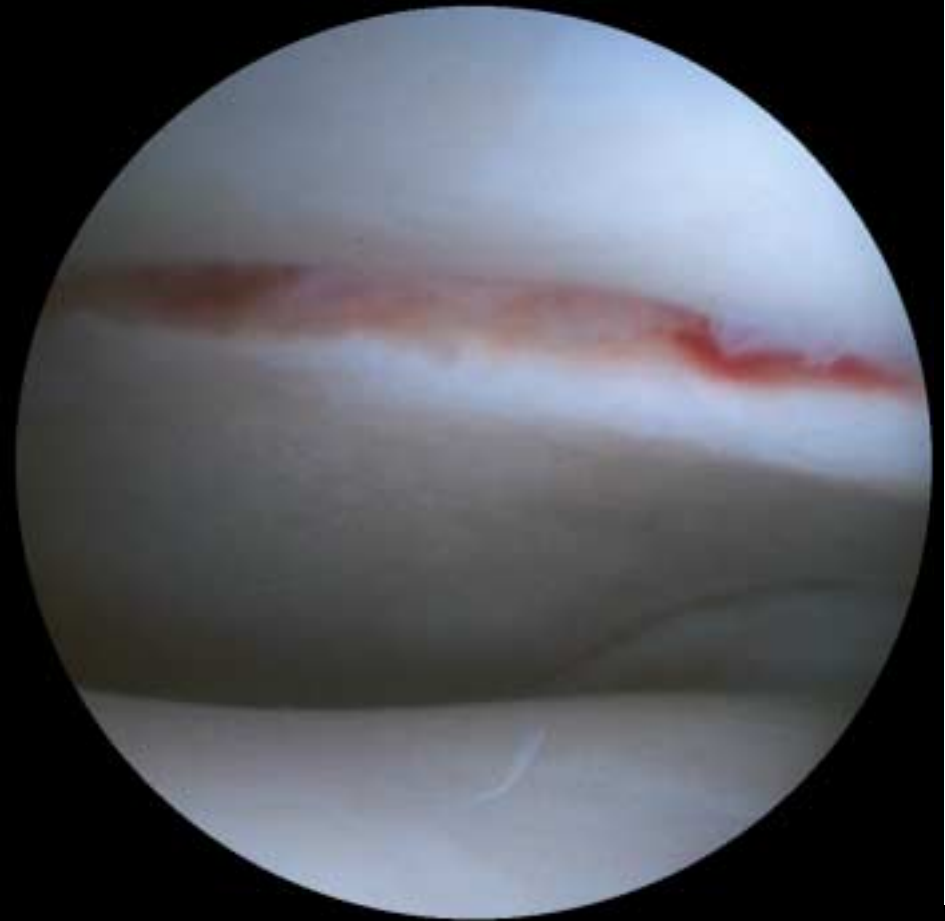

Ankle Arthroscopy

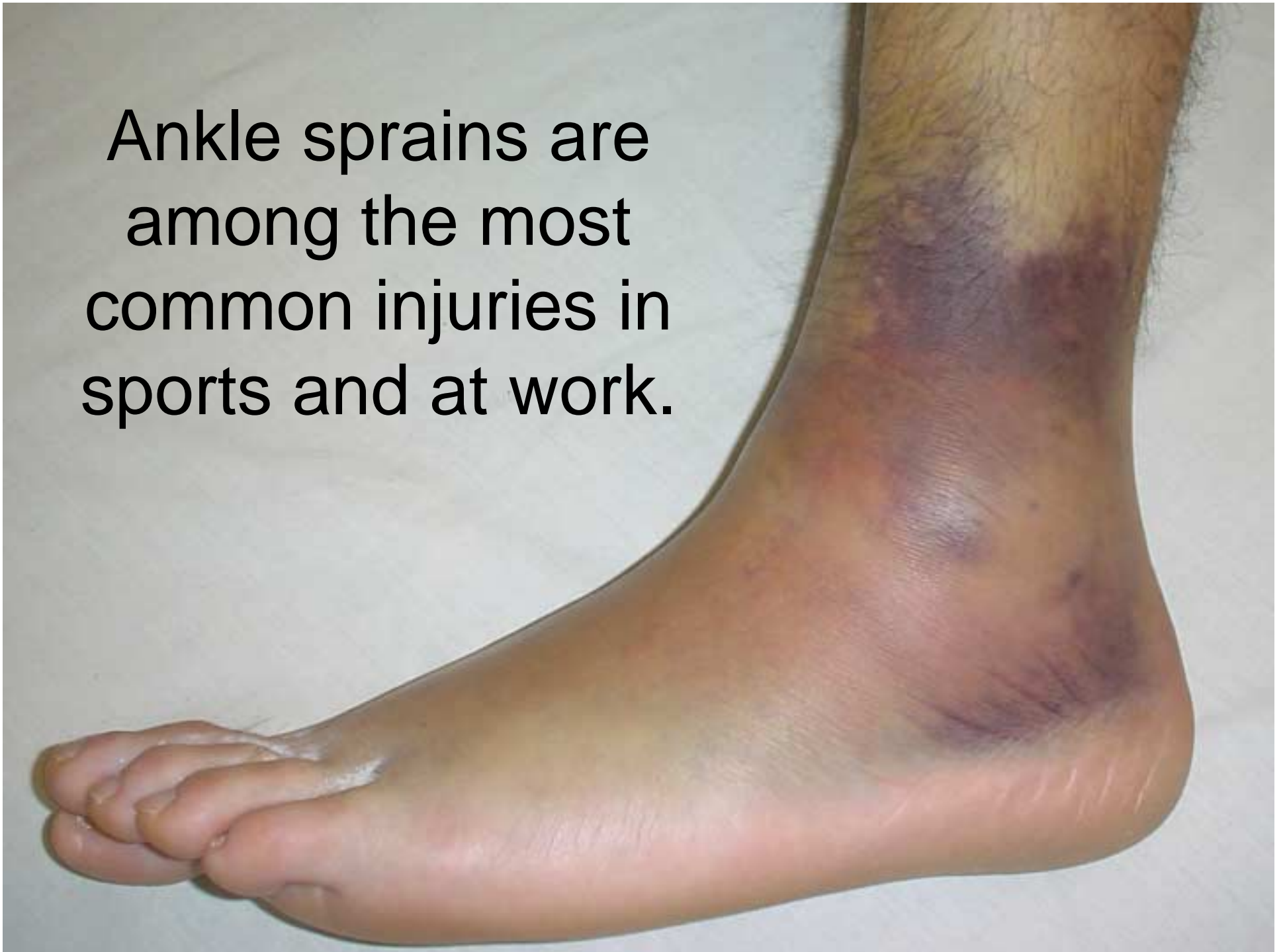

PAULO ROCKETT, M.D.

Porto Alegre  Brazil

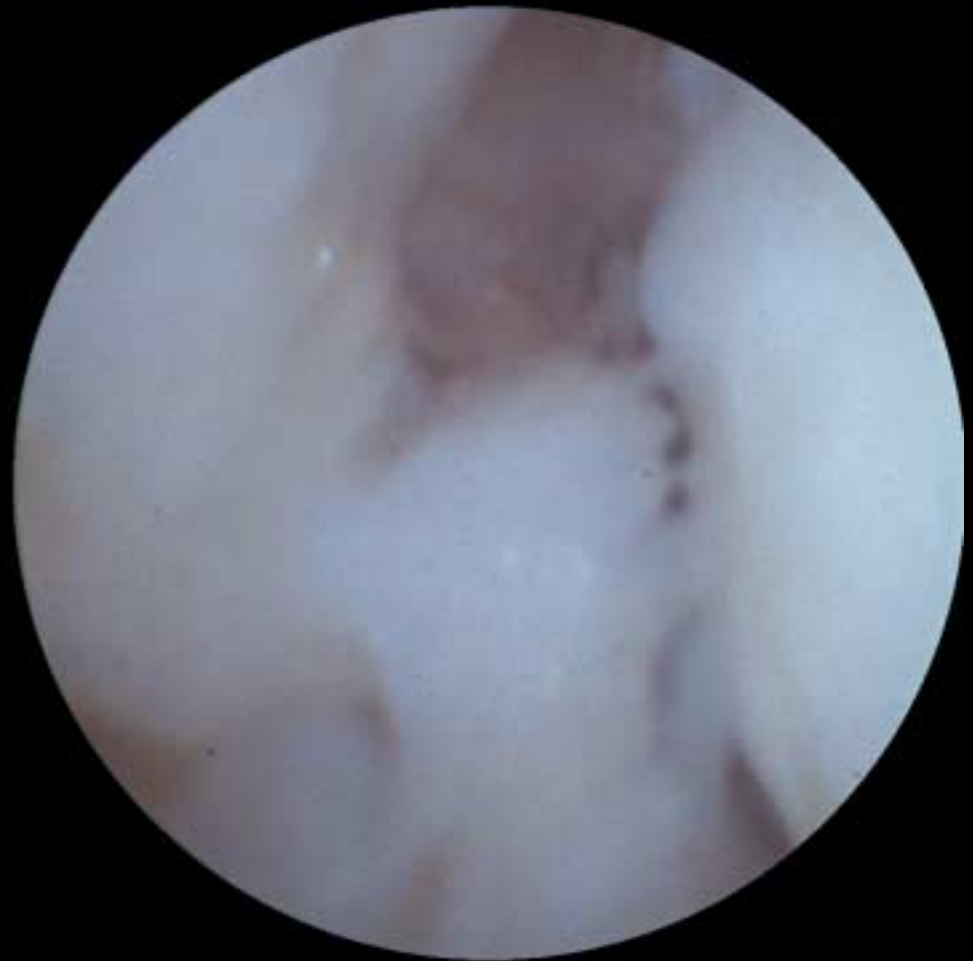

Ankle sprains are among the most common injuries in sports and at work.



Ankle Arthroscopy


Between 20 and 40% of patients treated with conservative therapy may have residual problems.



Ankle Arthroscopy

indications

- Articular injury
- Soft tissue impingement
- Bony impingement
- Some types of fractures (mild displacement)
- Synovitis
- Loose bodies and osteophytes
- Chondromalacia
- Osteochondral lesions of the talus

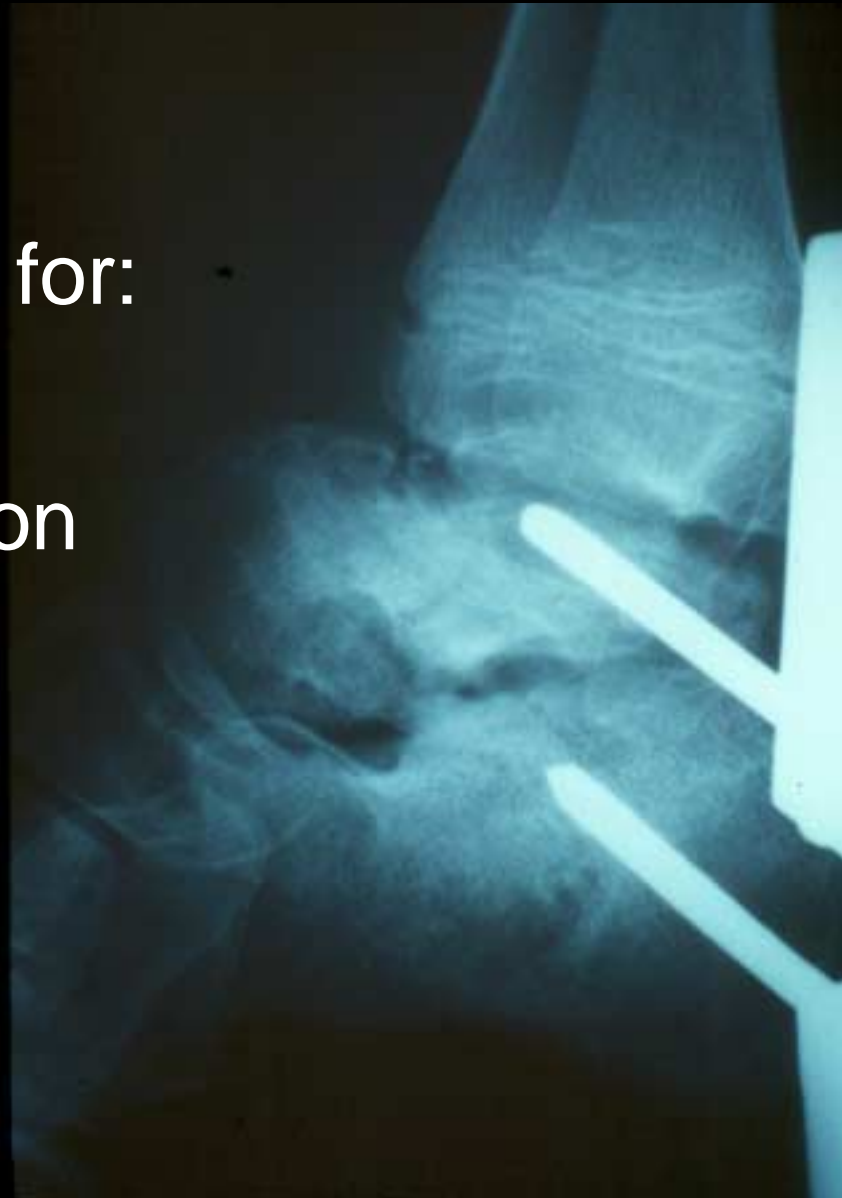

Ankle Arthroscopy

indications

May also be used for:

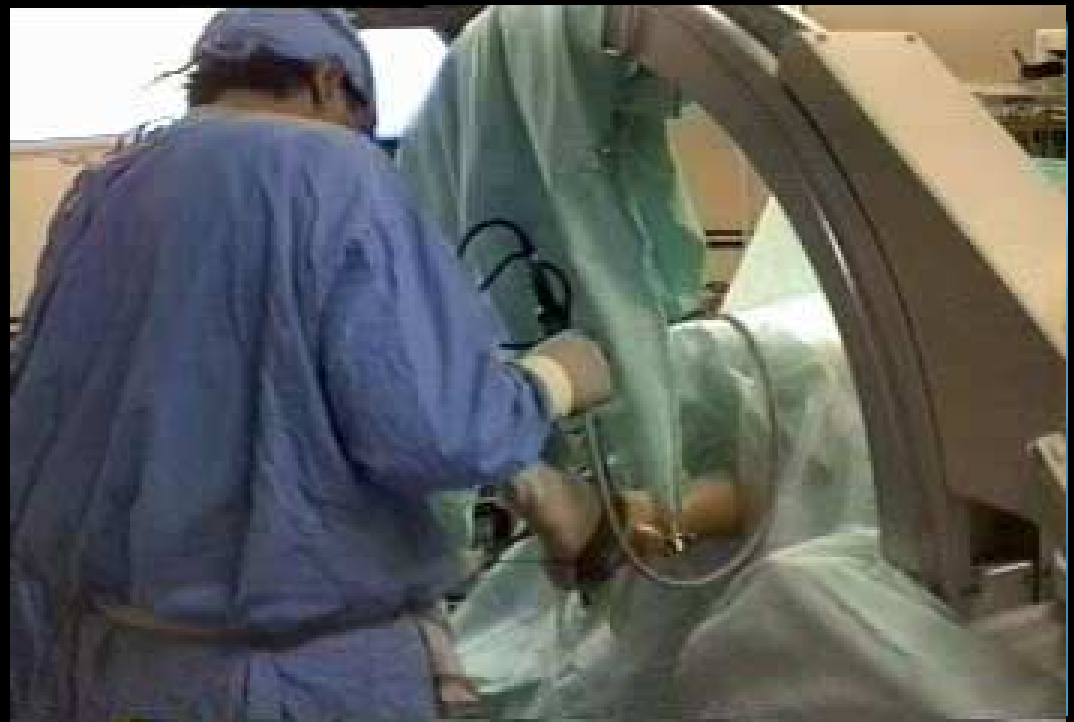- Ankle stabilization
- Arthrodesis



Ankle Arthroscopy

Author's technique

- Patients are placed in supine position
- Leg is secured in midportion with the leg-holder
- Noninvasive joint distraction
- Establish portals - dull dissection
- Cannula system

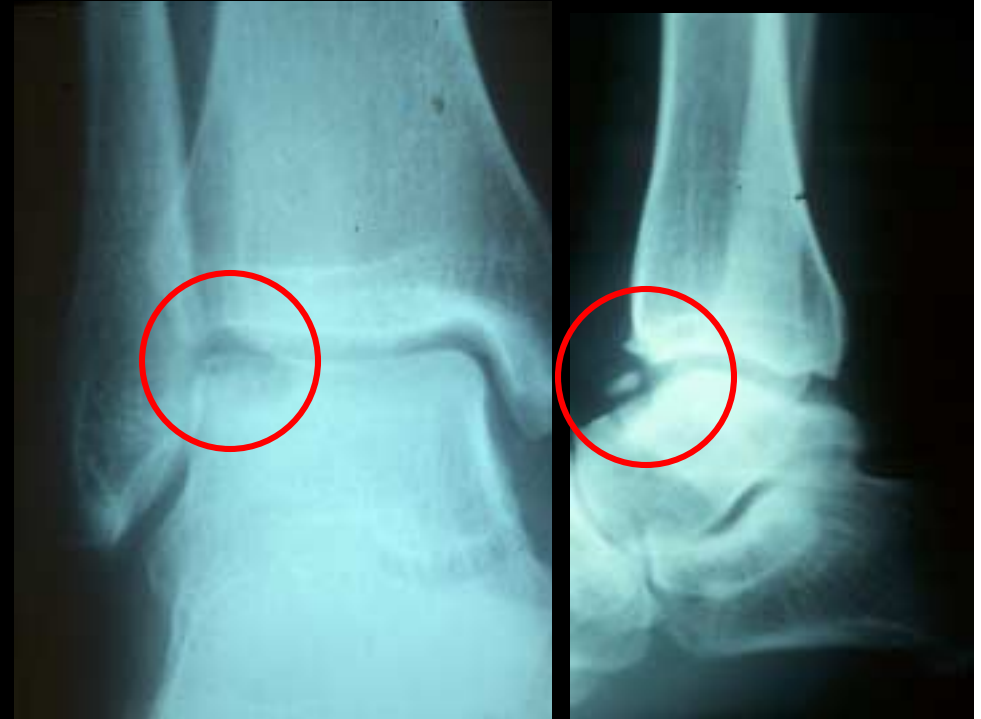

Ankle Arthroscopy

portals

Anterior

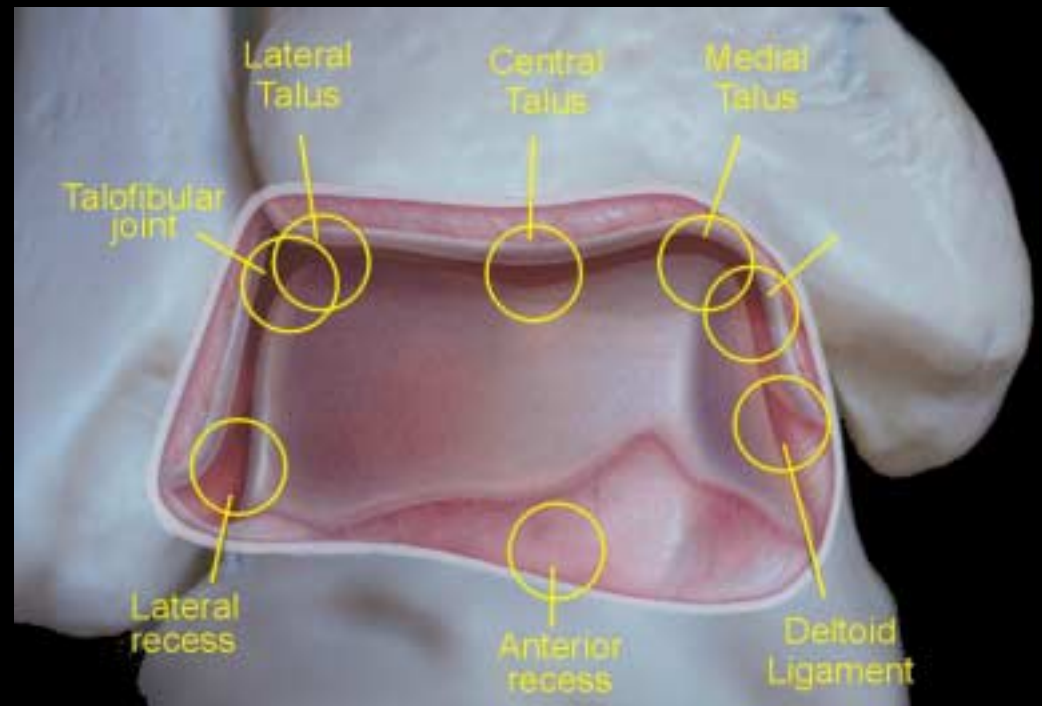
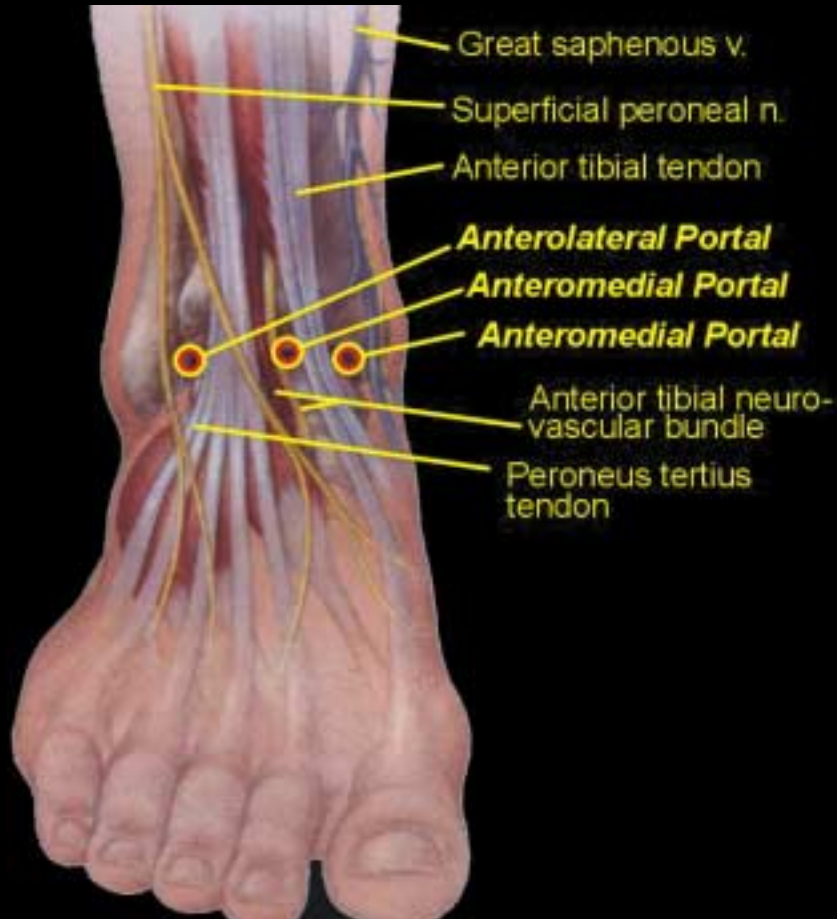- Anterolateral
- Anteromedial
- Anterocentral



Ankle Arthroscopy

portals

Anterior

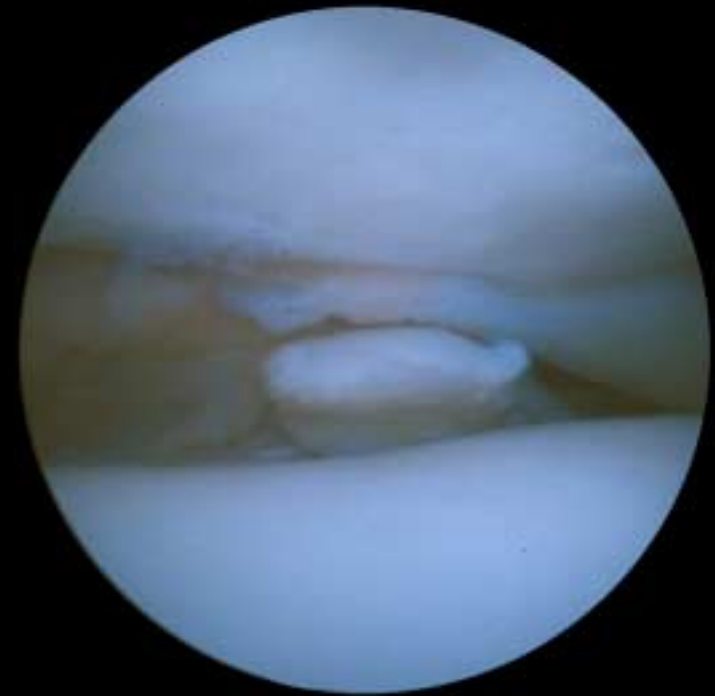
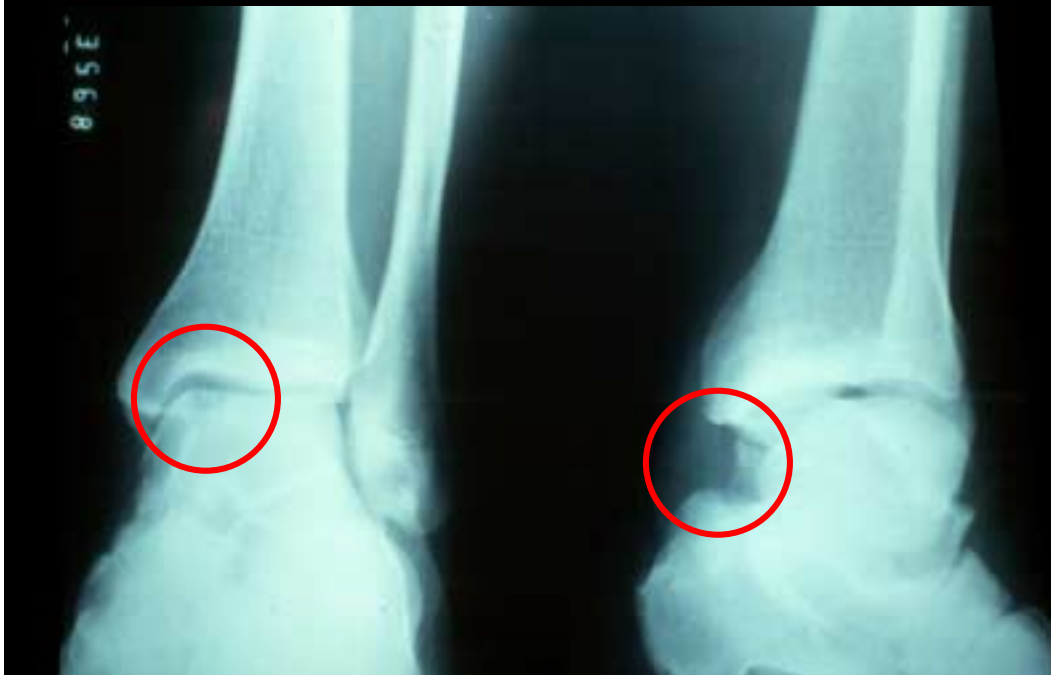

Ankle Arthroscopy

portals

Posterior

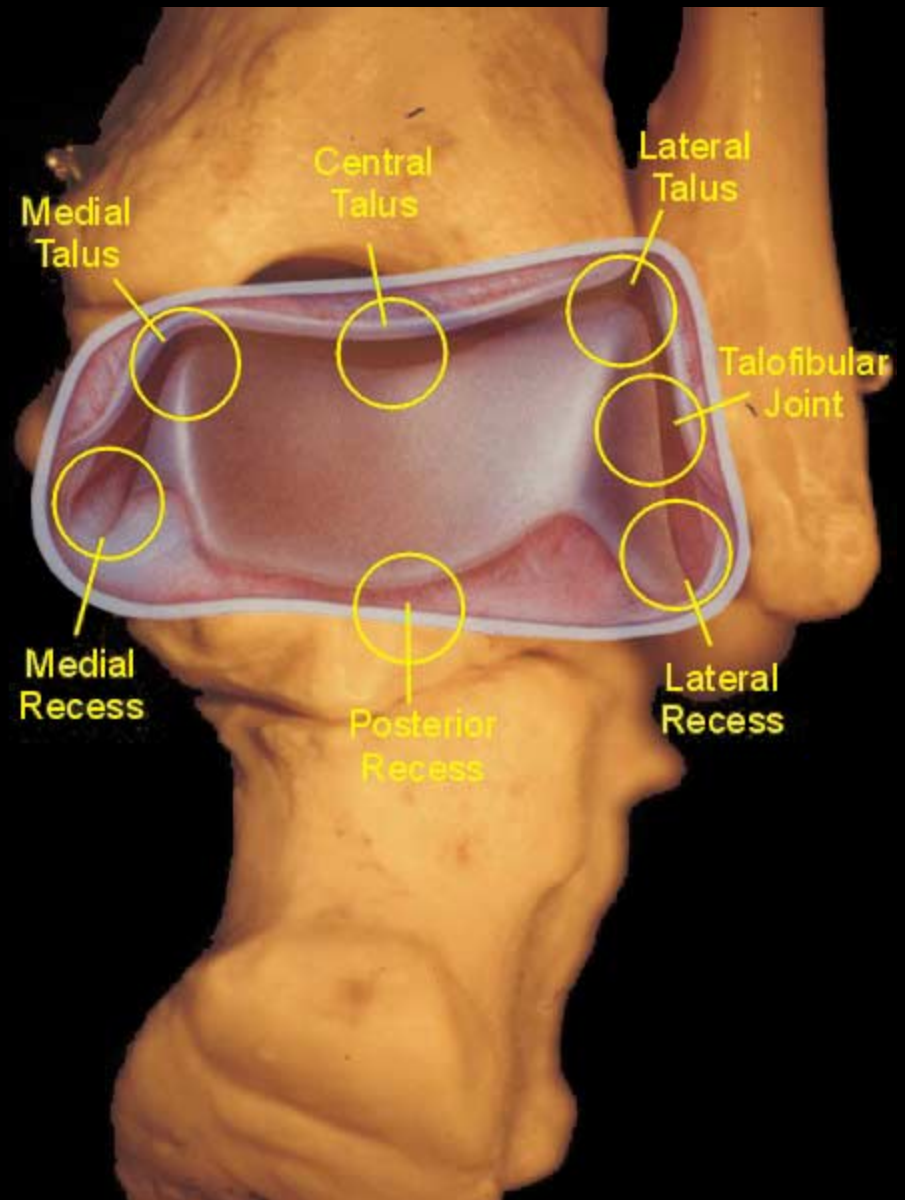
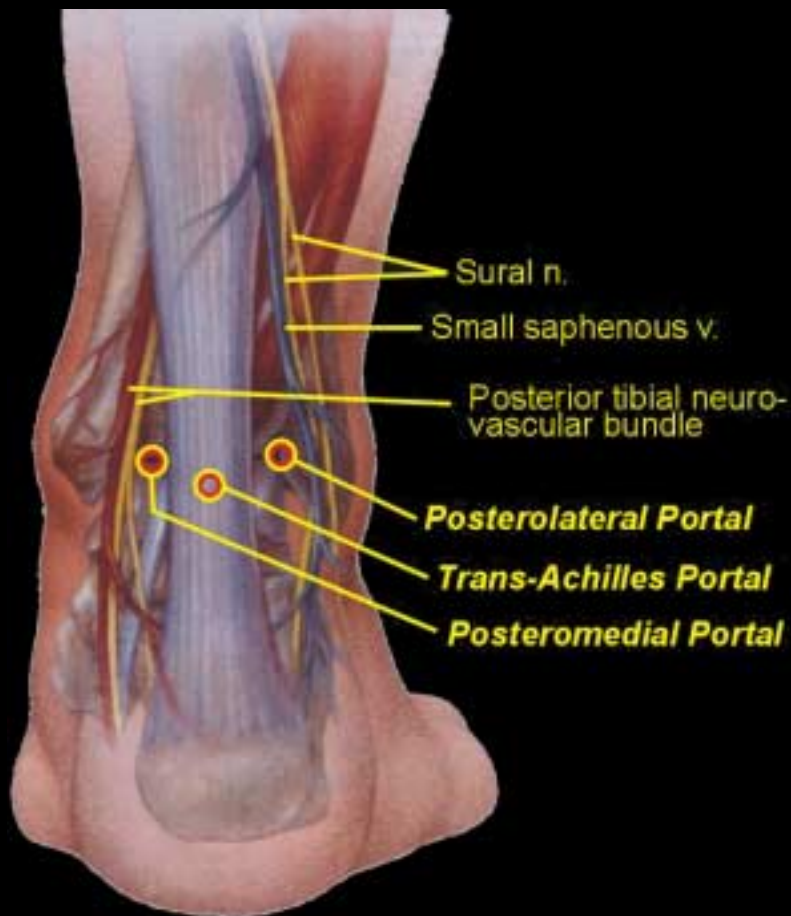- Posterolateral
- Trans-Achilles tendon
- Posteromedial



Ankle Arthroscopy

portals

Posterior



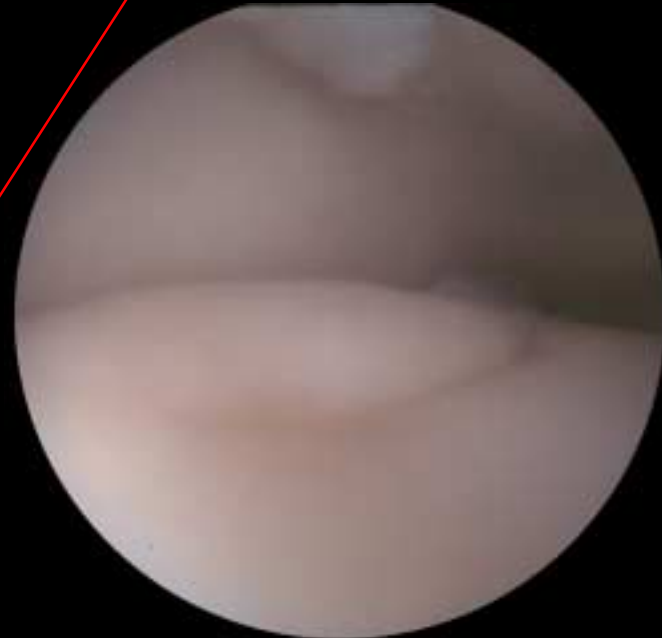
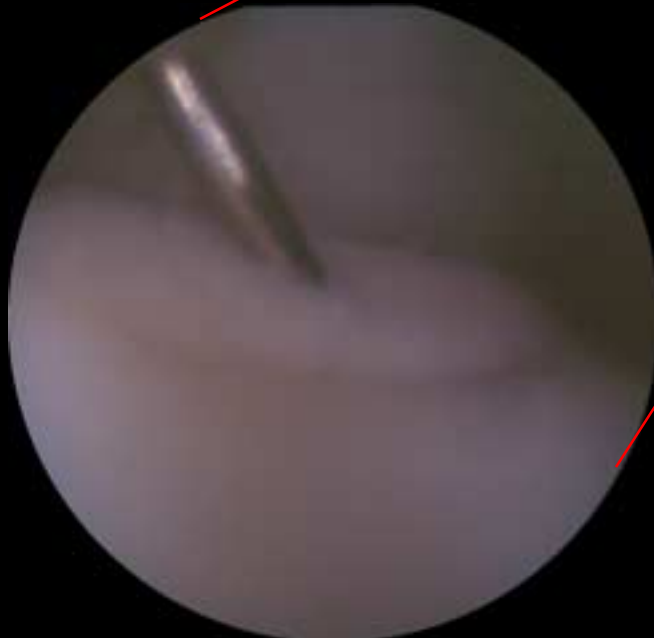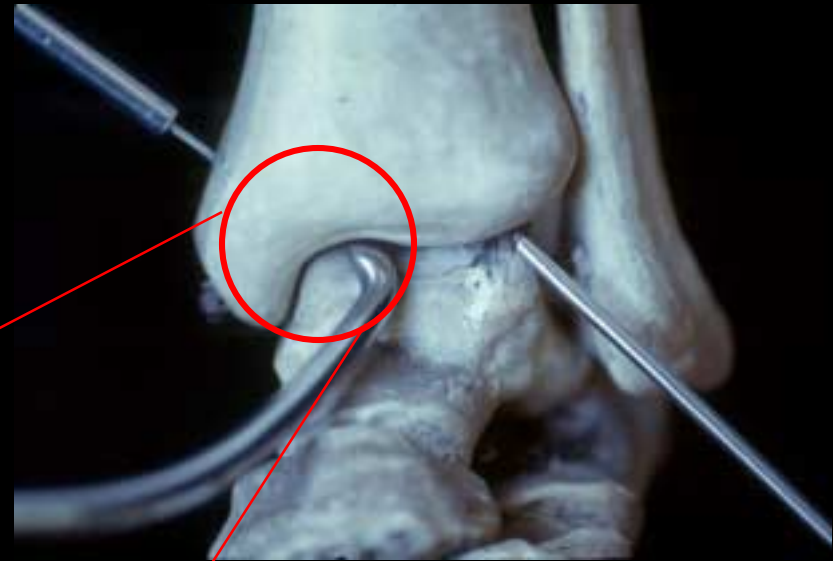
Ankle Arthroscopy

portals

Transmalleolar

● Medial

● Lateral



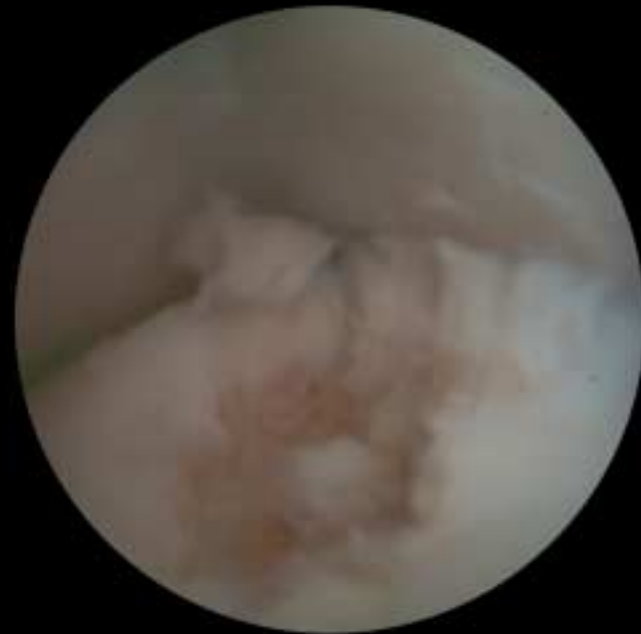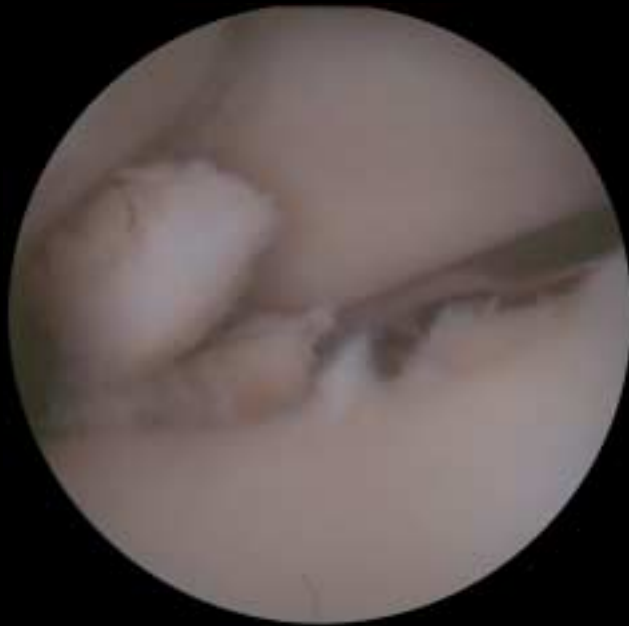Ankle Arthroscopy

complications

- Damage to neurovascular structures and tendons
- Chondral injuries
- Synovial fistula

Ankle Arthroscopy

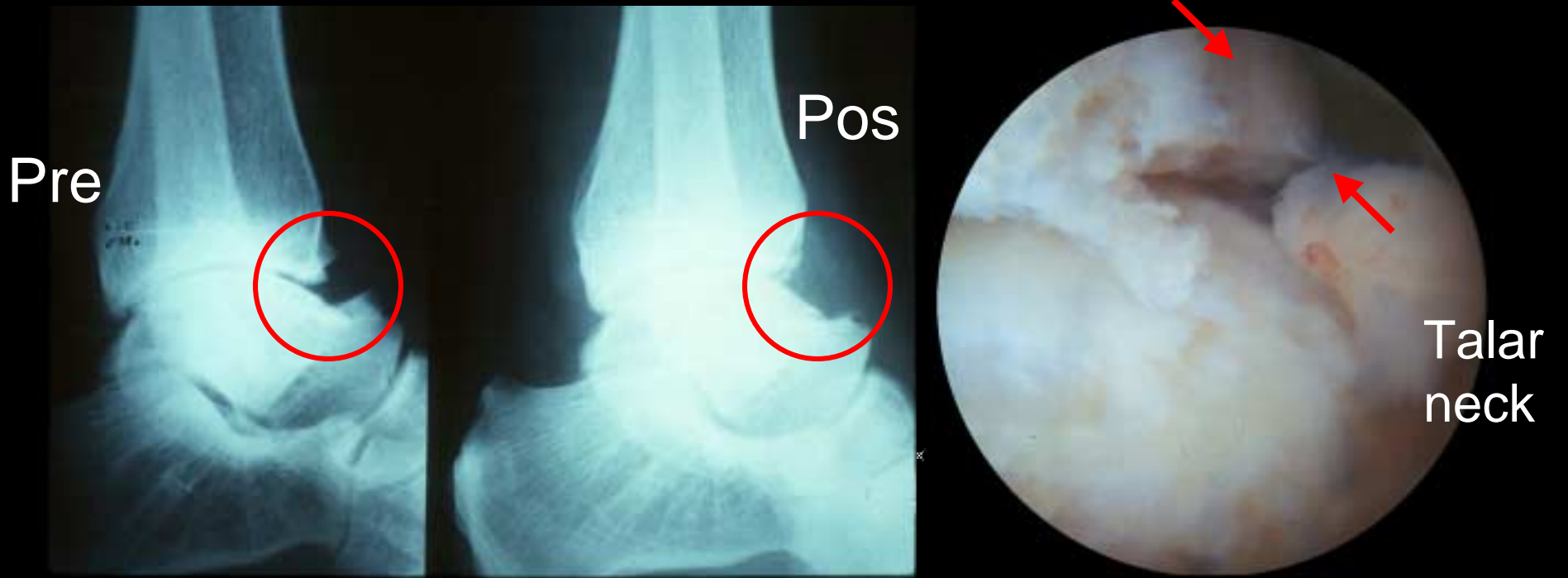- Anterior bony impingement (arthritic conditions, loose bodies and fractures)
- Anterolateral soft tissue impingement (synovitis or scar tissue)
- **Osteochondritis dissecans**



Ankle Arthroscopy

anterior bony impingement

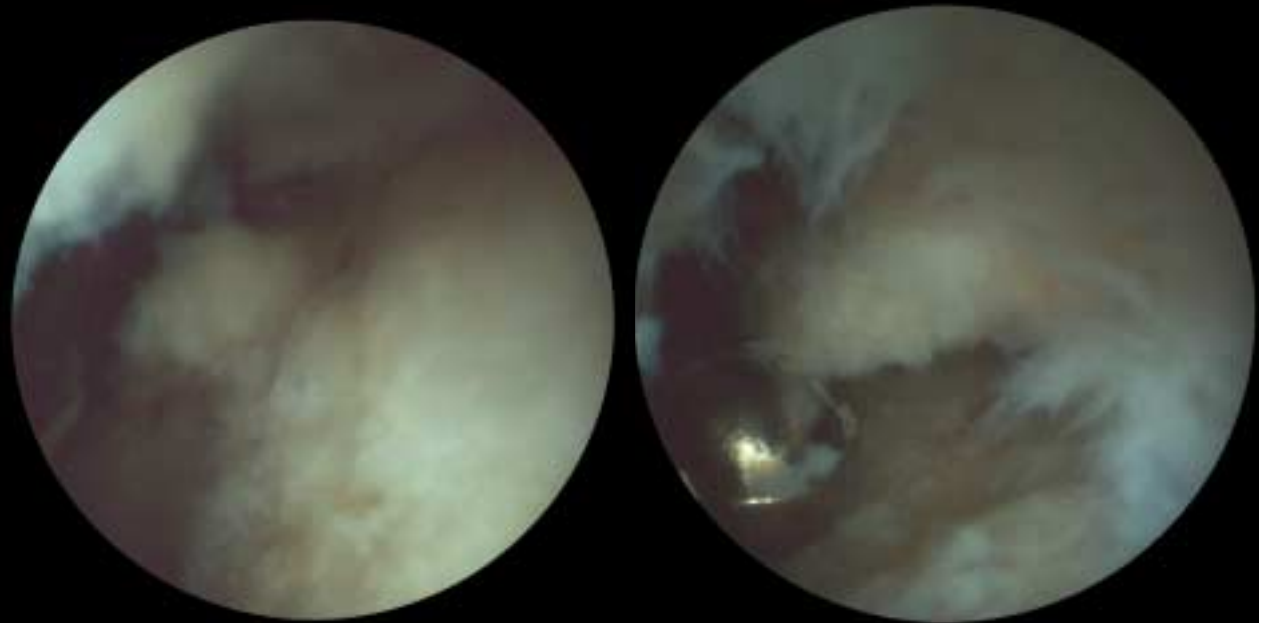
- Pain on forced dorsiflexion
- X-Rays confirm exostoses



Ankle Arthroscopy

anterior bony impingement

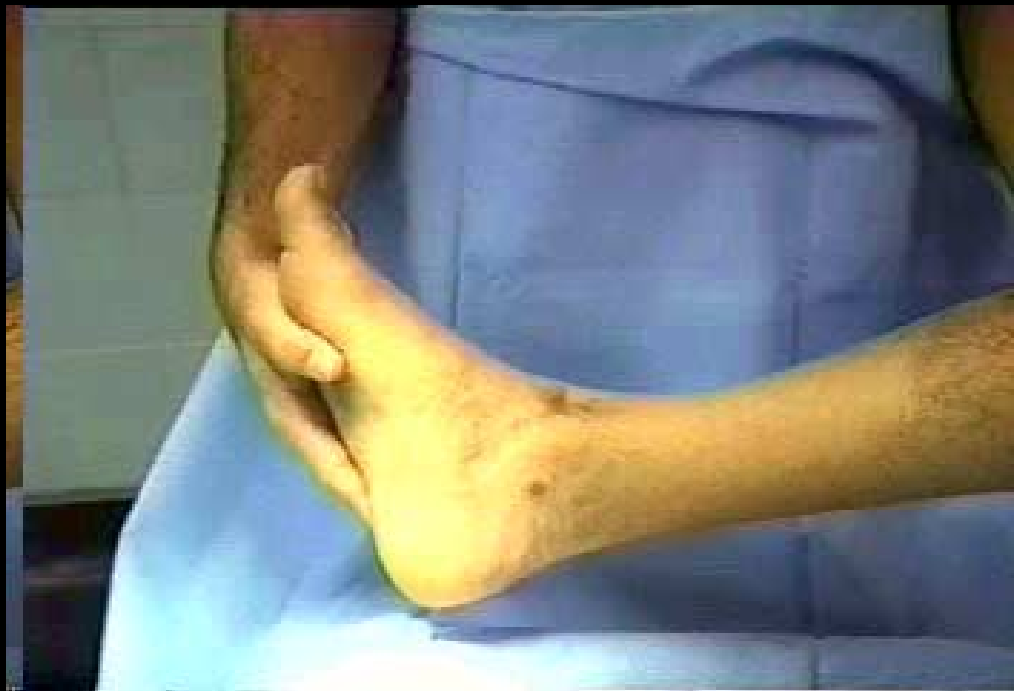- Osteoarthritis of the ankle
- Osteophytes of anterior lip of the tibia
- Osteophytes at the talar neck
- **Chondral lesion of the talar dome (tram track)**
- Loose bodies



Ankle Arthroscopy

anterior bony impingement treatment

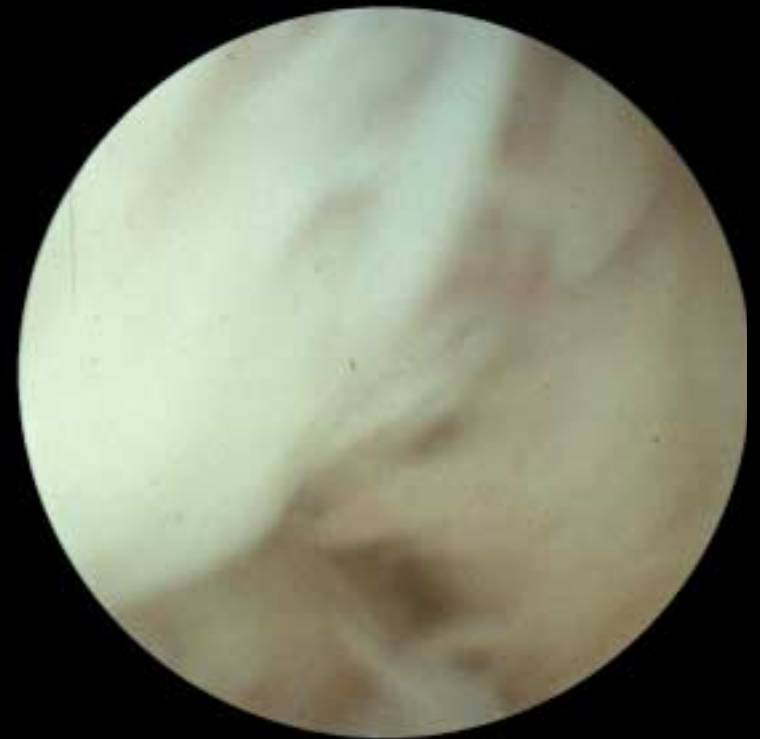- **Excision of exostoses (tibial and talar neck)**
- Distraction is essential in avoiding injury to the talar articular surface
- Partial synovectomy
- Abrasion or drilling of chondral lesion (tram track)



Ankle Arthroscopy

anterolateral soft tissue impingement

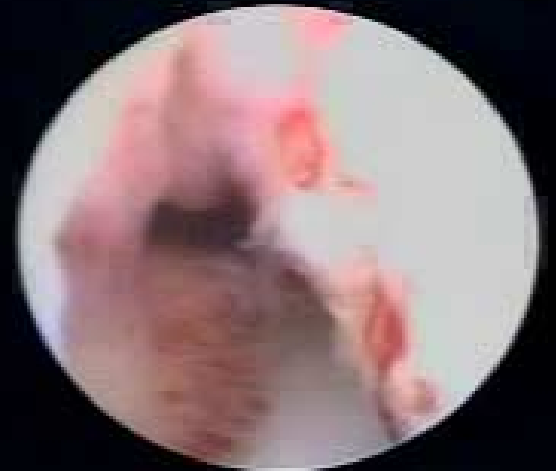- History of sprain and pseudo-instability
- Pain and tenderness anterolateral joint
- Pain with eversion and dorsiflexion
- Positive response to local injection
- MRI has minimal benefit



Ankle Arthroscopy

anterolateral soft tissue impingement

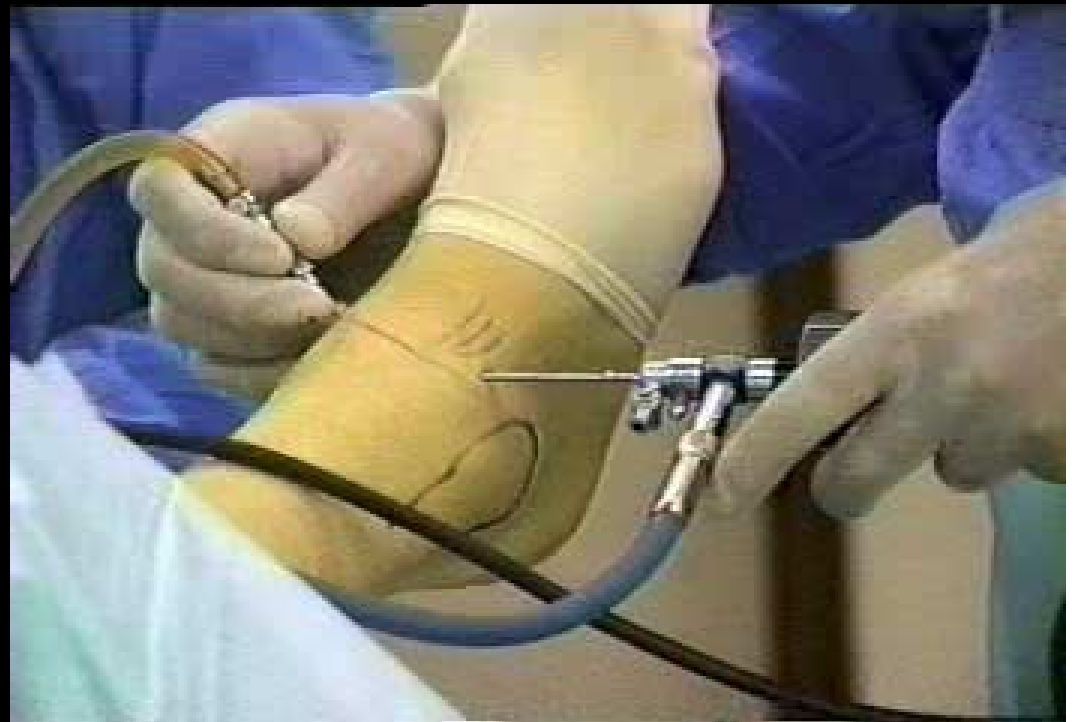- Injuries to lateral capsule
- Torn anterior ligaments (tibiofibular, talofibular)
- Synovitis or scar tissue that becomes trapped between bony structures
- May erode lateral talar dome ridge



Ankle Arthroscopy

anterolateral soft tissue impingement treatment

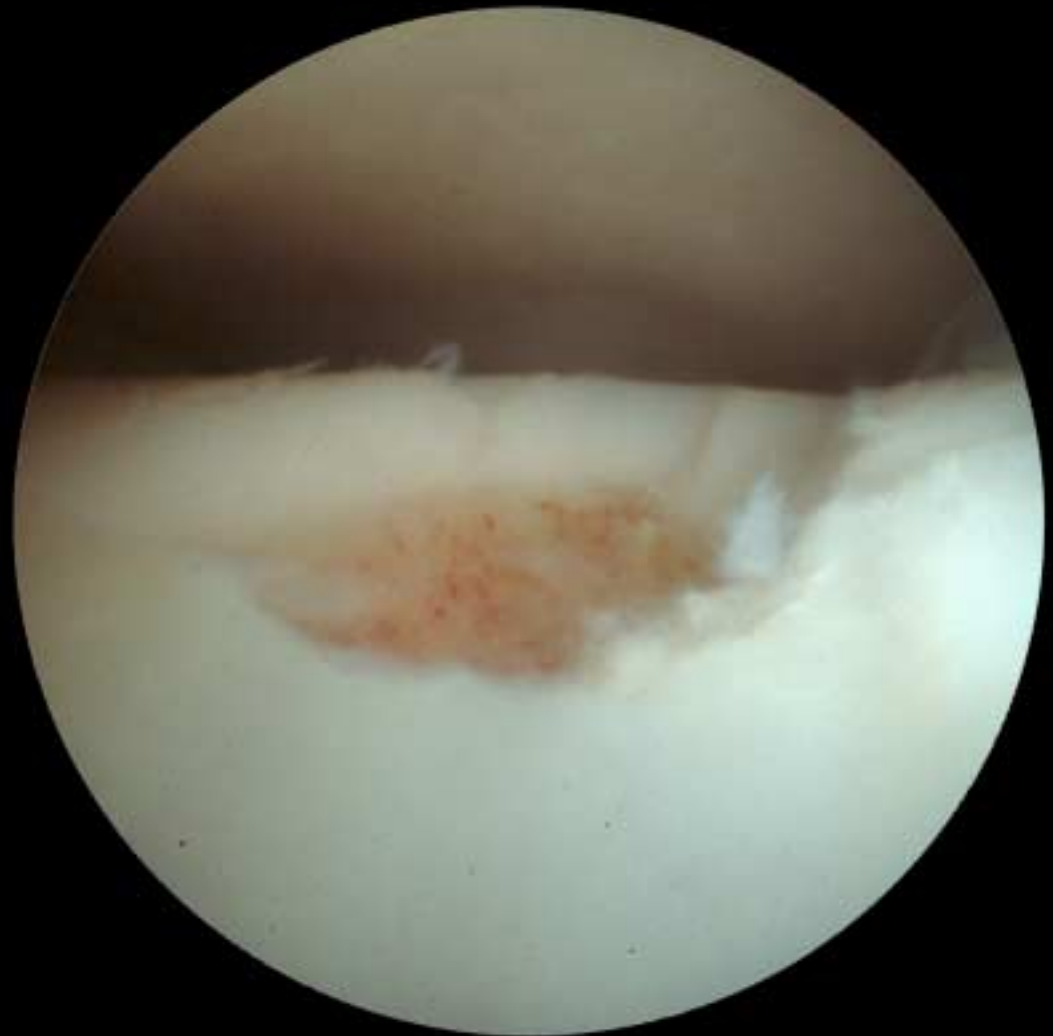- Partial synovectomy
- Do not resect capsule
- Do not resect remained ligament
- Chondrectomy – talar dome ridge



Ankle Arthroscopy

osteochondritis dissecans

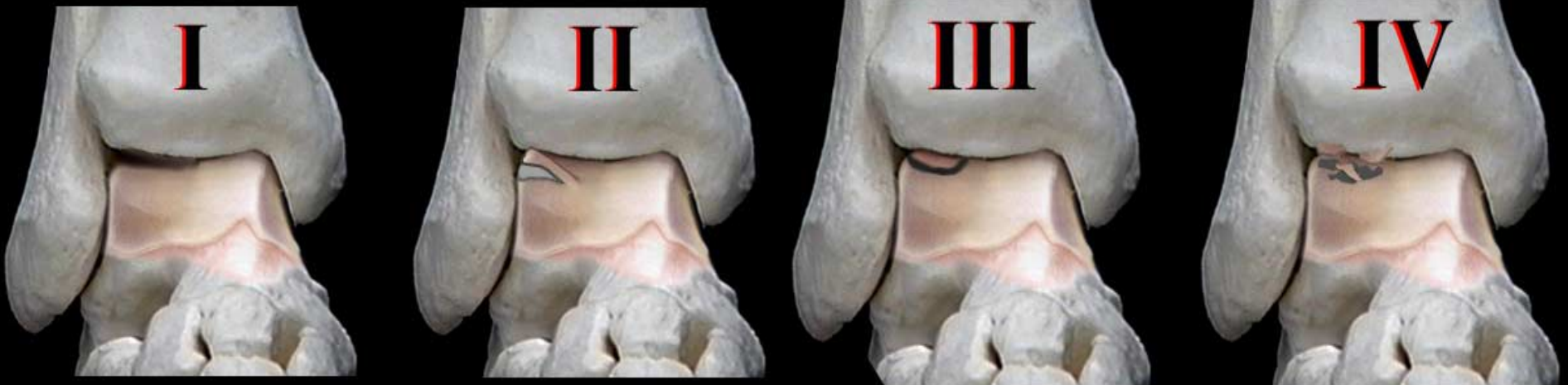
- Pain
- Catching
- Grinding
- Intermittent swelling



Ankle Arthroscopy

osteochoondritis dissecans

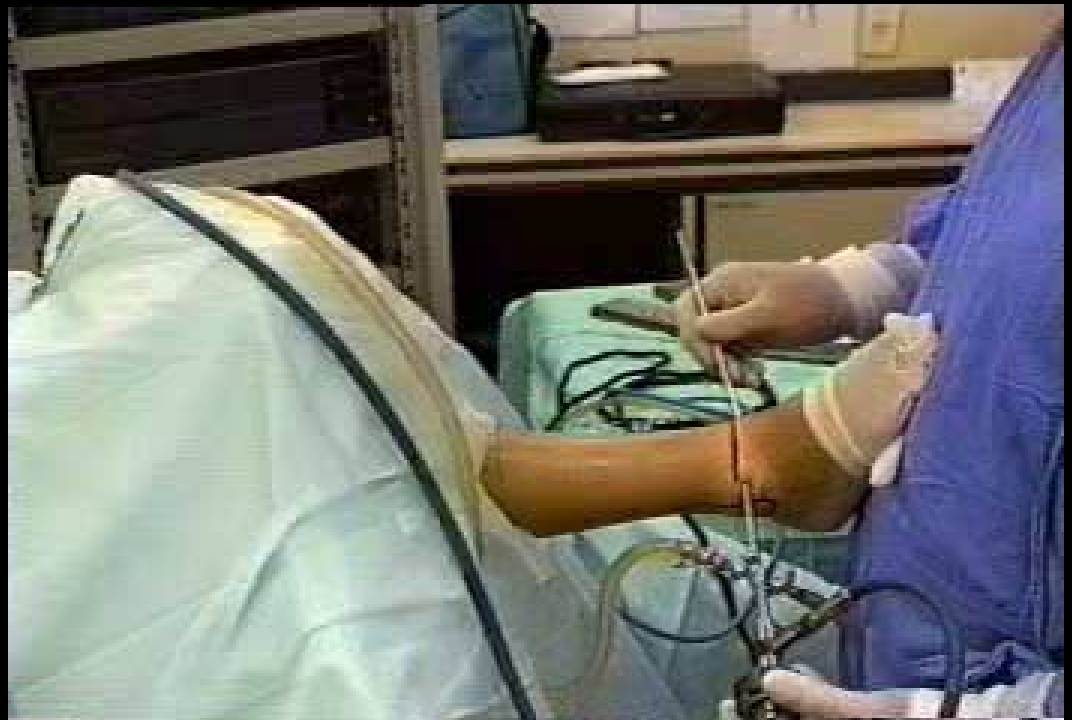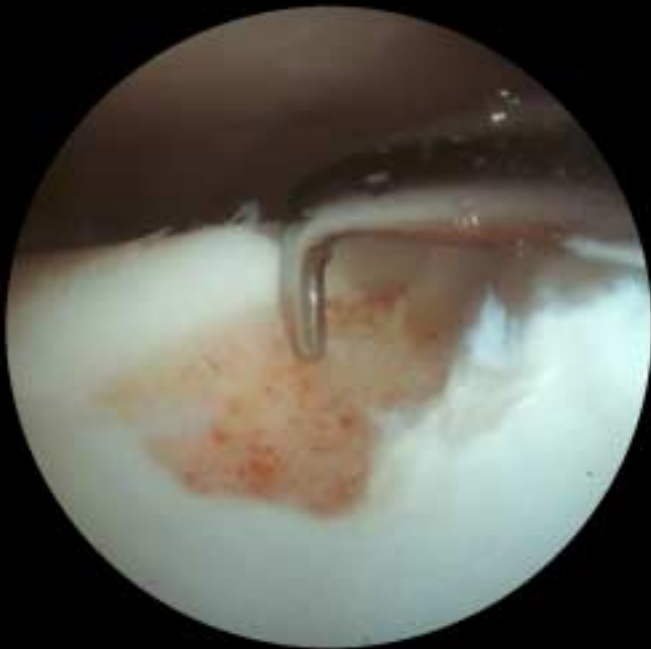- **Stage I, II or III** (Berndt and Harty classification) with persistent symptoms after an adequate nonoperative therapy (up to 3 months) would benefit with arthroscopy.
- **Stage IV** should be treated surgically.



Ankle Arthroscopy

osteochondritis dissecans

- Removal of loose bodies
- Curettage or drilling
- Fixation (>2cm)



Ankle Arthroscopy

method

37 patients

Symptoms of chronic ankle pain
that had failed to respond to
conservative treatment for
at least 6 months.

Ankle Arthroscopy

method

37 patients

Sex

- 11 women
- 26 men

Age:

- minimum 13 y.o.
- maximum 81 y.o.

Follow-up:

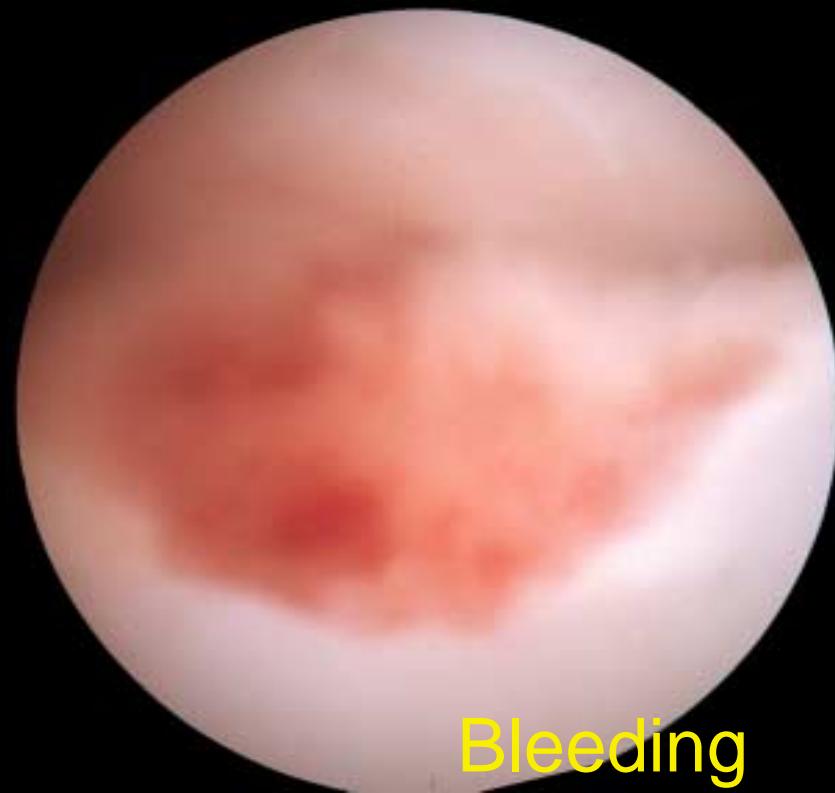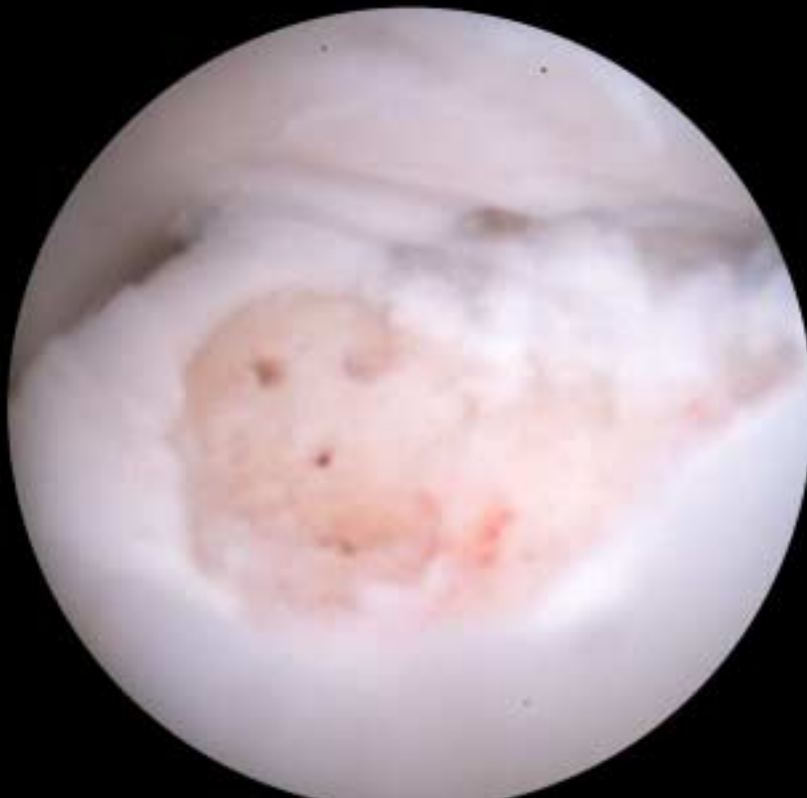
- minimum 2 years
- maximum 10 years
- average 6 years

Ankle Arthroscopy

method

37 patients

Osteochondritis dissecans (OCD)	6
---------------------------------	---



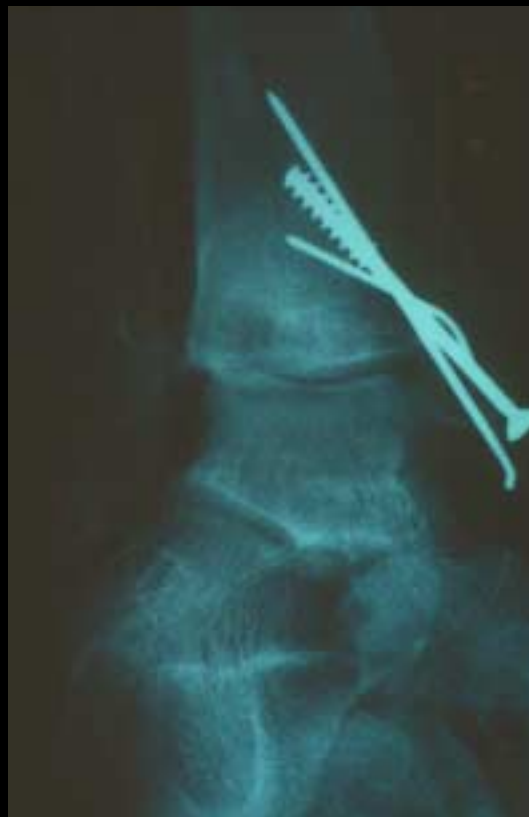Bleeding

Ankle Arthroscopy

method

37 patients

Post ankle fracture	3
---------------------	---



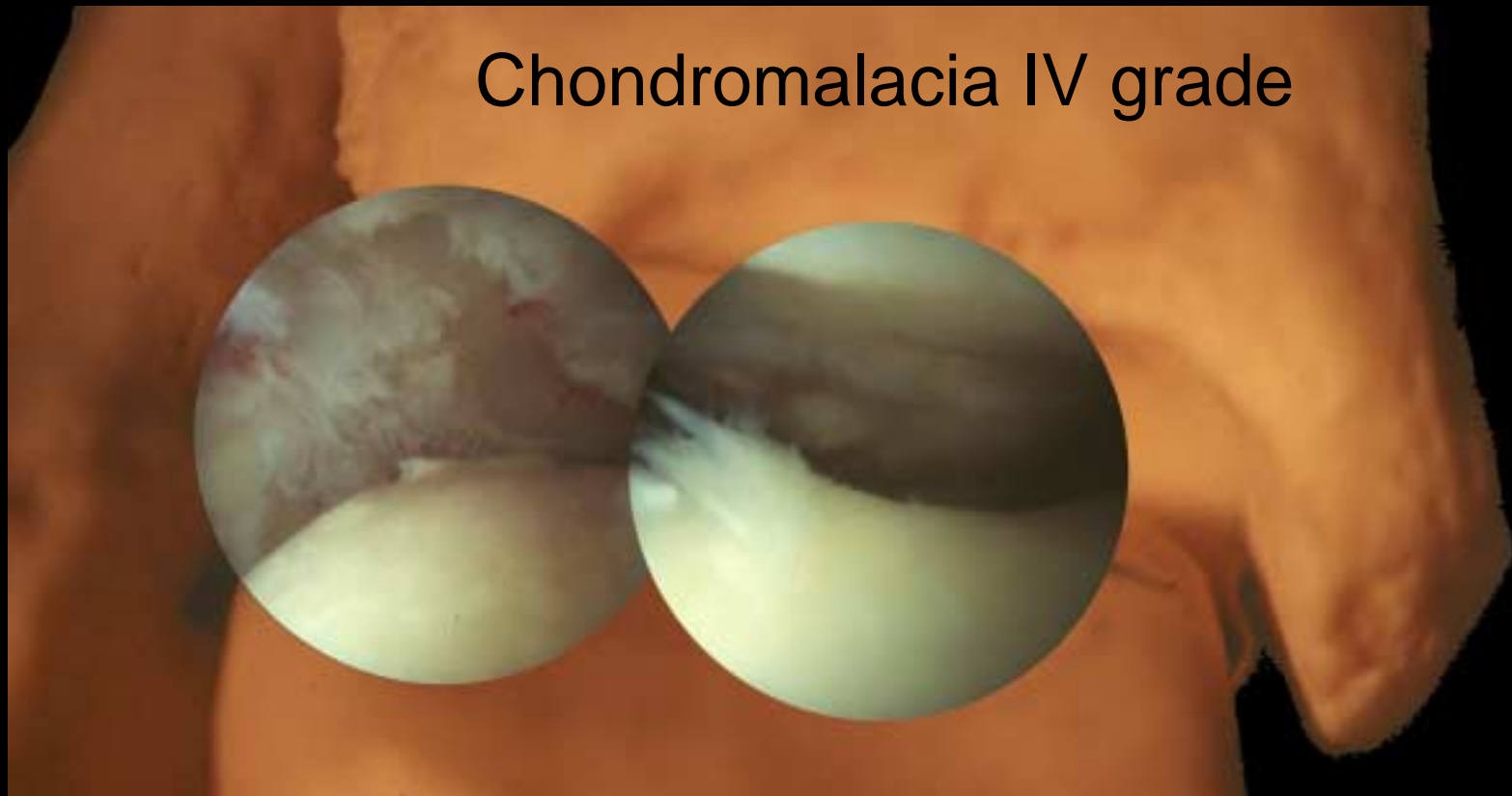Ankle Arthroscopy

method

37 patients

Post ankle fracture	3
---------------------	---

Chondromalacia IV grade



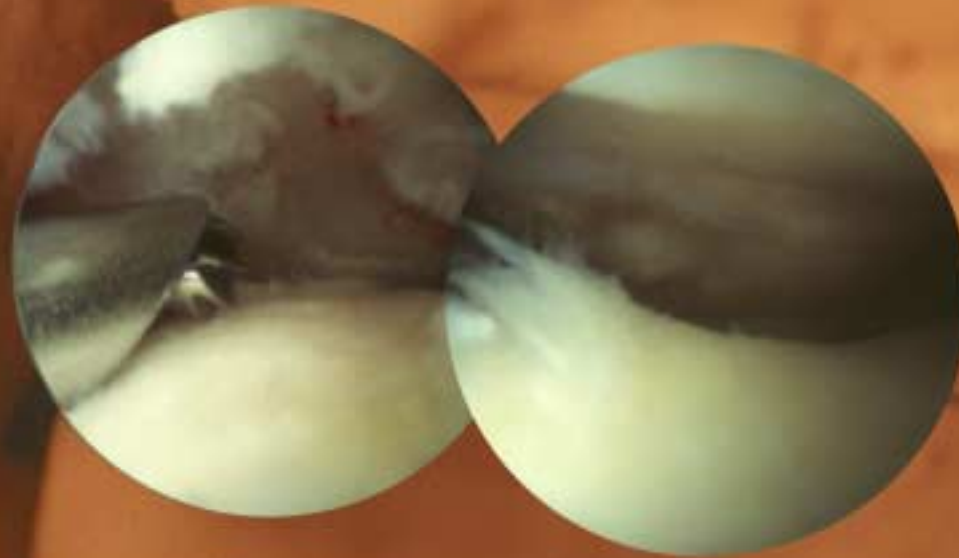
Ankle Arthroscopy

method

37 patients

Post ankle fracture	3
---------------------	---

Debridement and abrasion



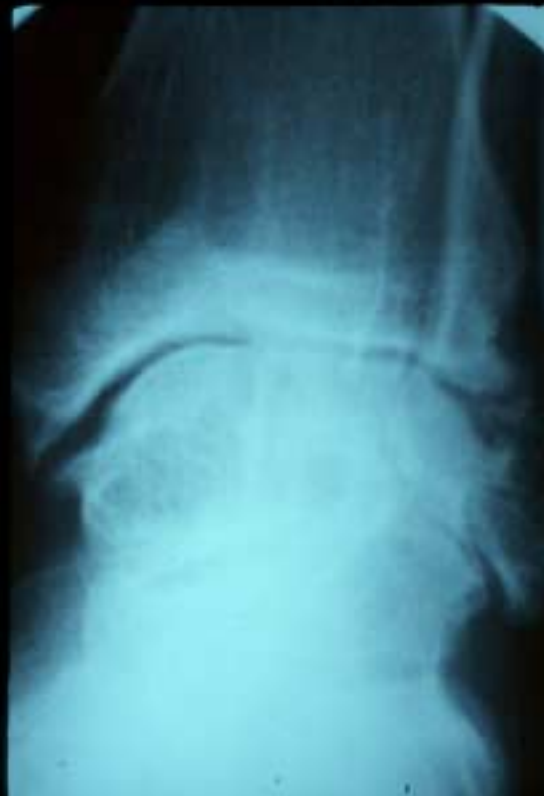Ankle Arthroscopy

method

37 patients

Osteoarthritis and chondromalacia

2

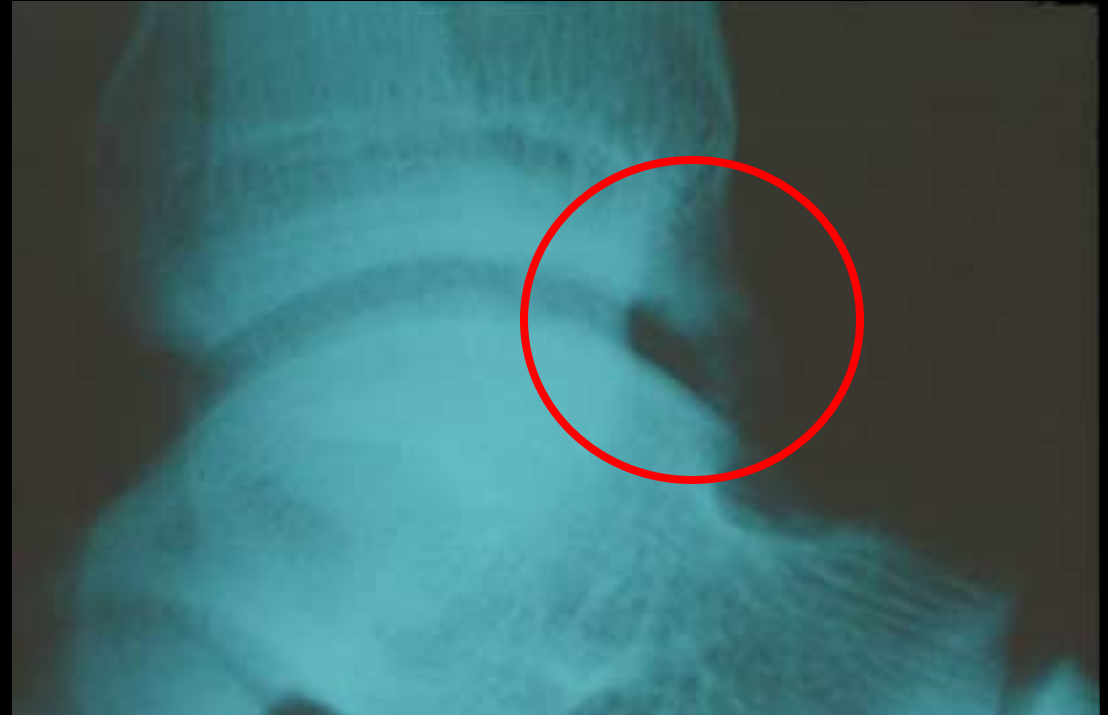
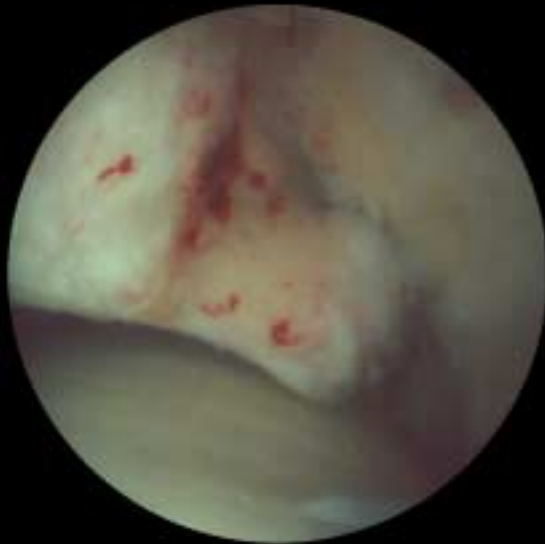
✦ Ankle Arthroscopy

✦ *method*

37 patients

Anterior bony impingement	7
---------------------------	---



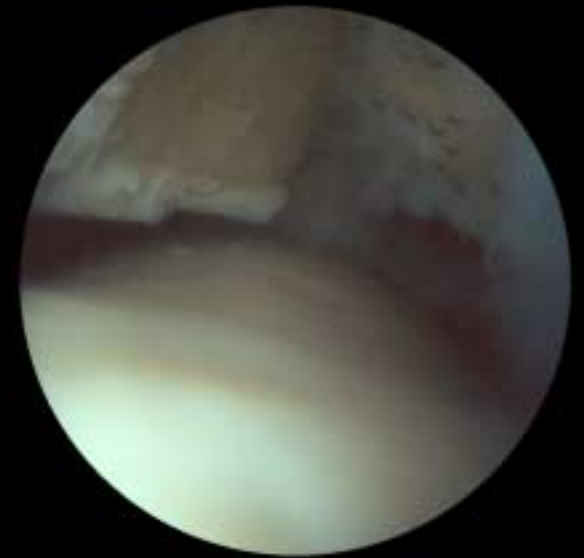
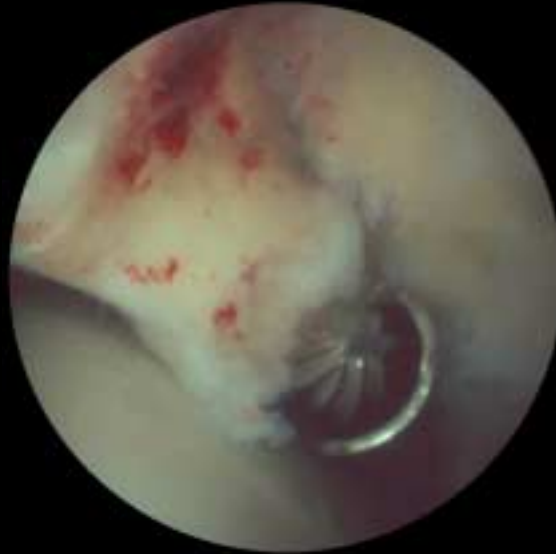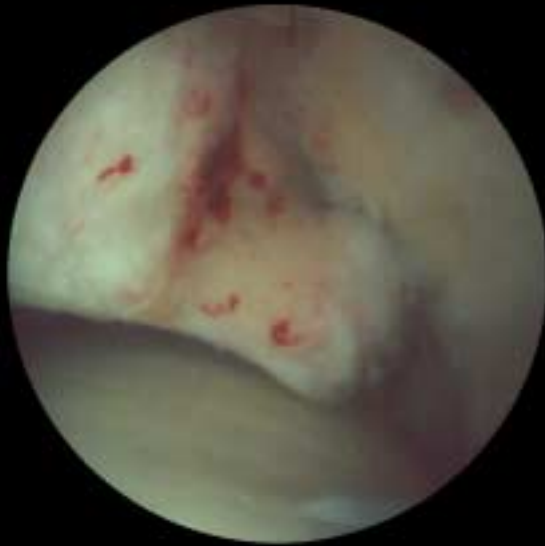Ankle Arthroscopy

method

37 patients

Anterior bony impingement	7
---------------------------	---

Osteophyte

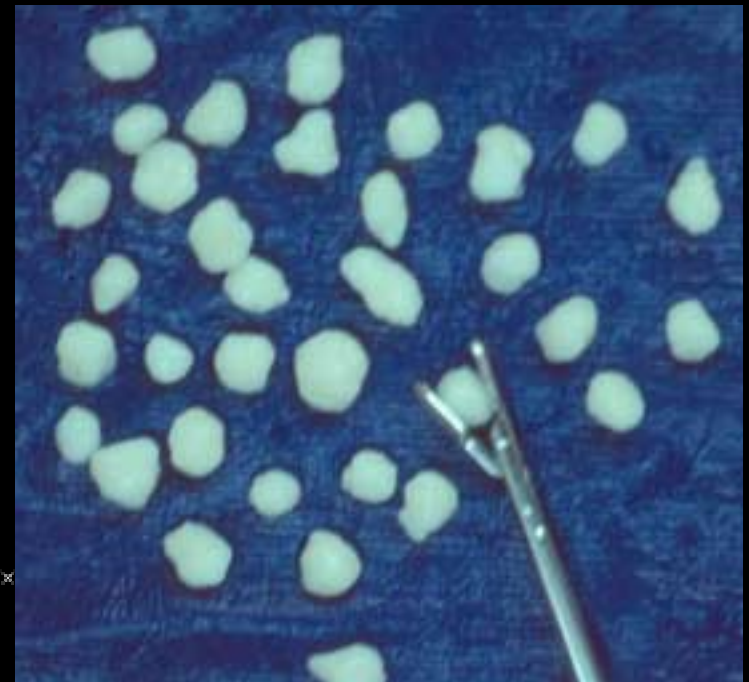
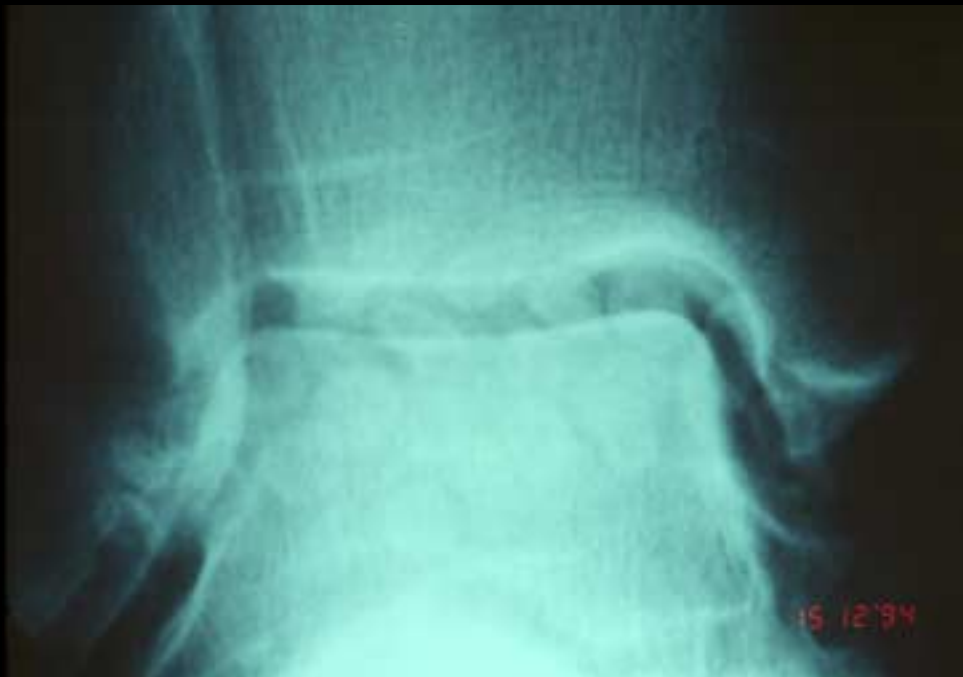
Ankle Arthroscopy

method

37 patients

Loose bodies	4
--------------	---

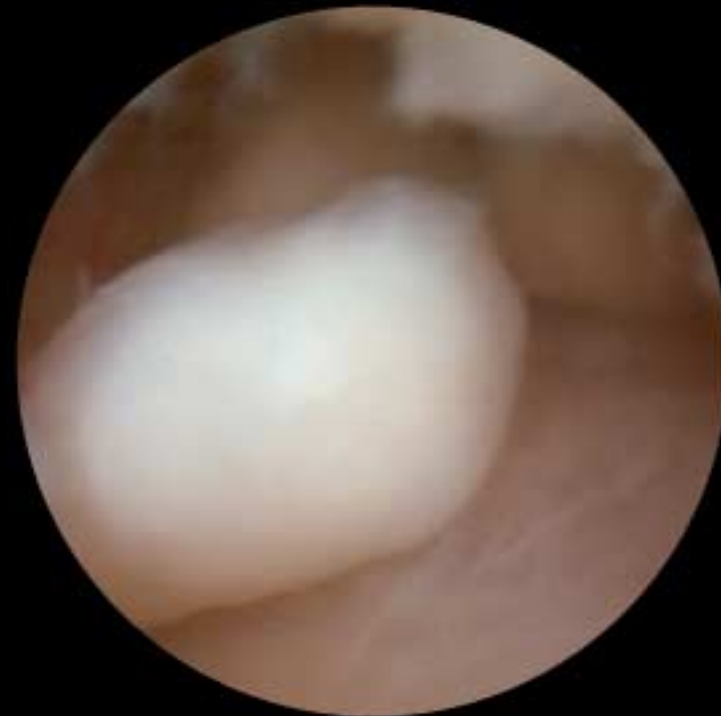
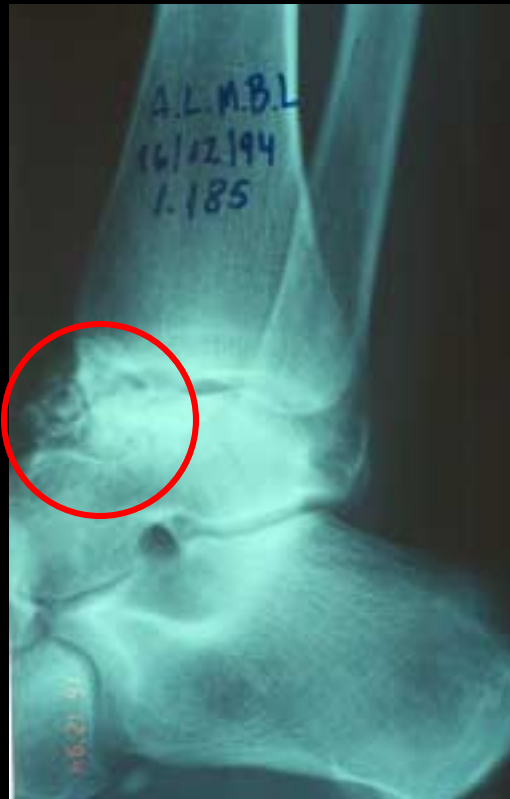
Ankle Arthroscopy

method

37 patients

Loose bodies	4
--------------	---

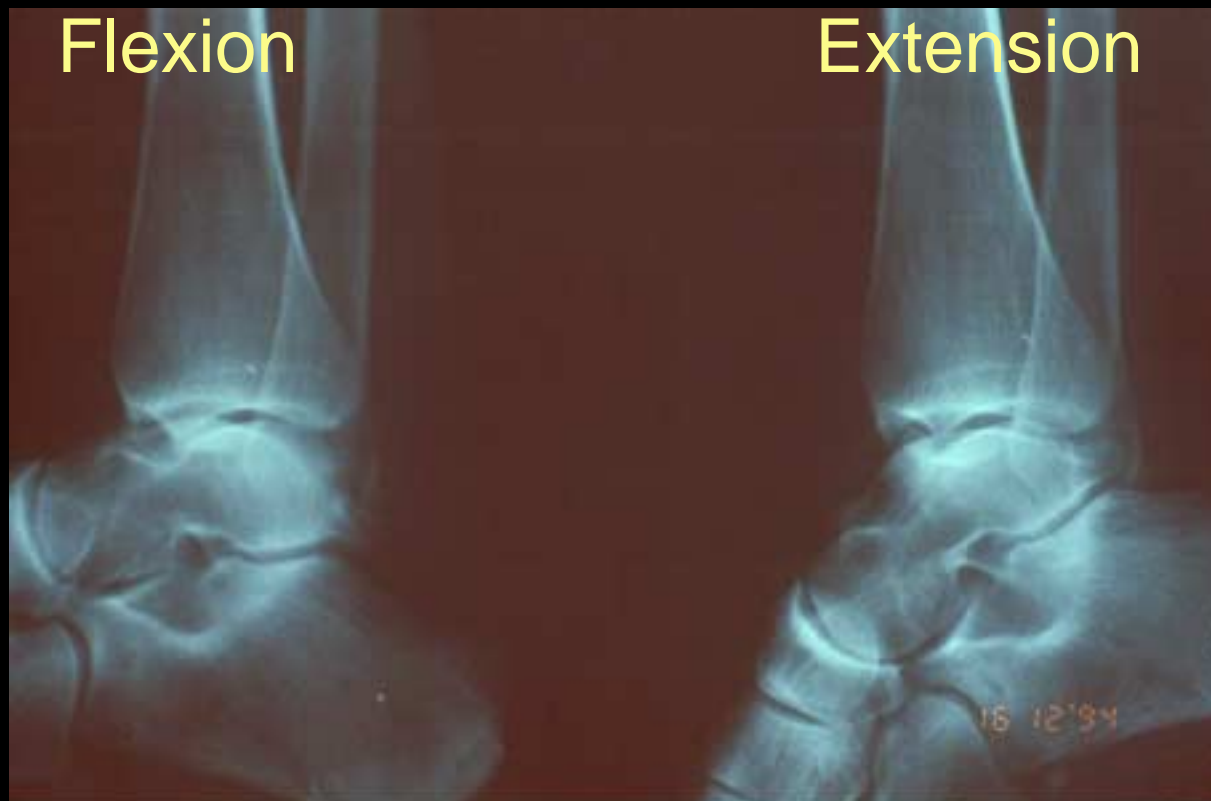


Ankle Arthroscopy

method

37 patients

Loose bodies	4
--------------	---



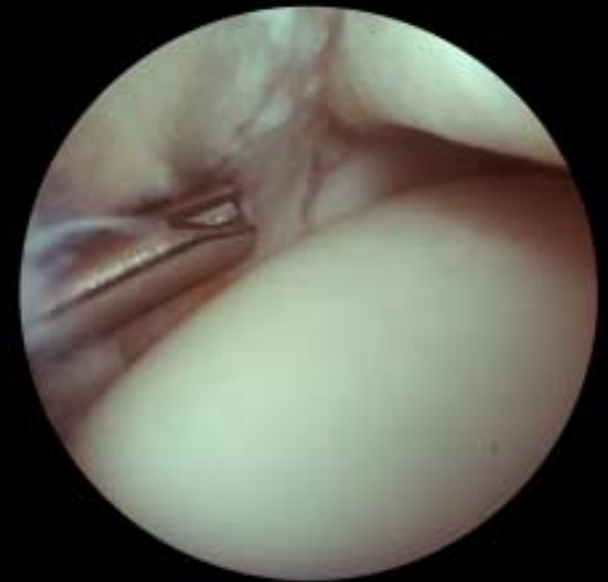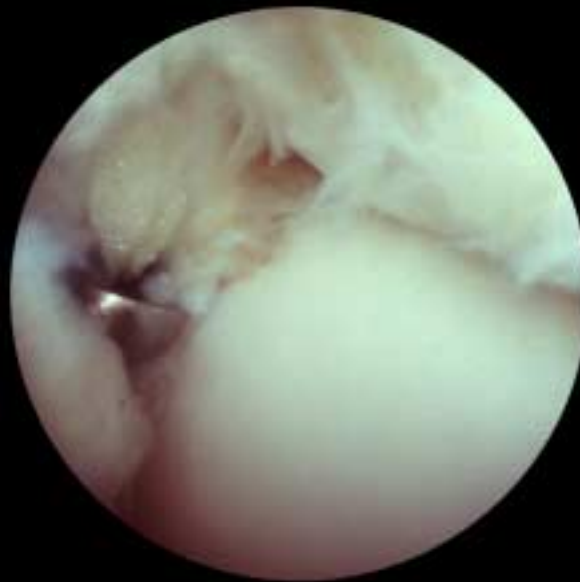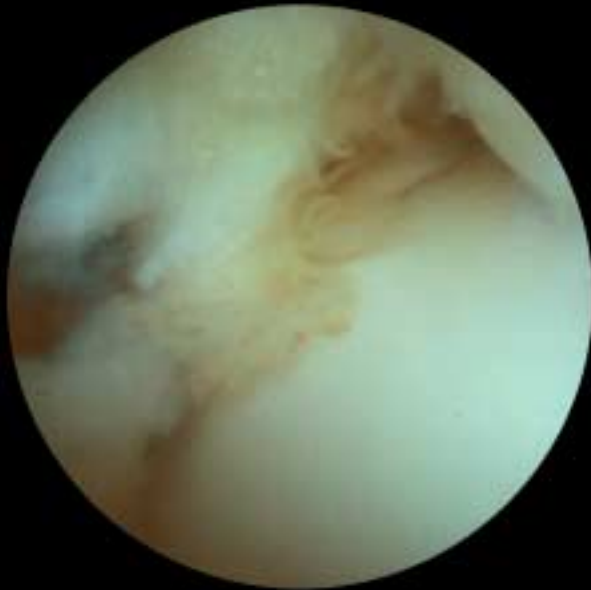
Ankle Arthroscopy

method

37 patients

Anterolateral soft tissue impingement

14



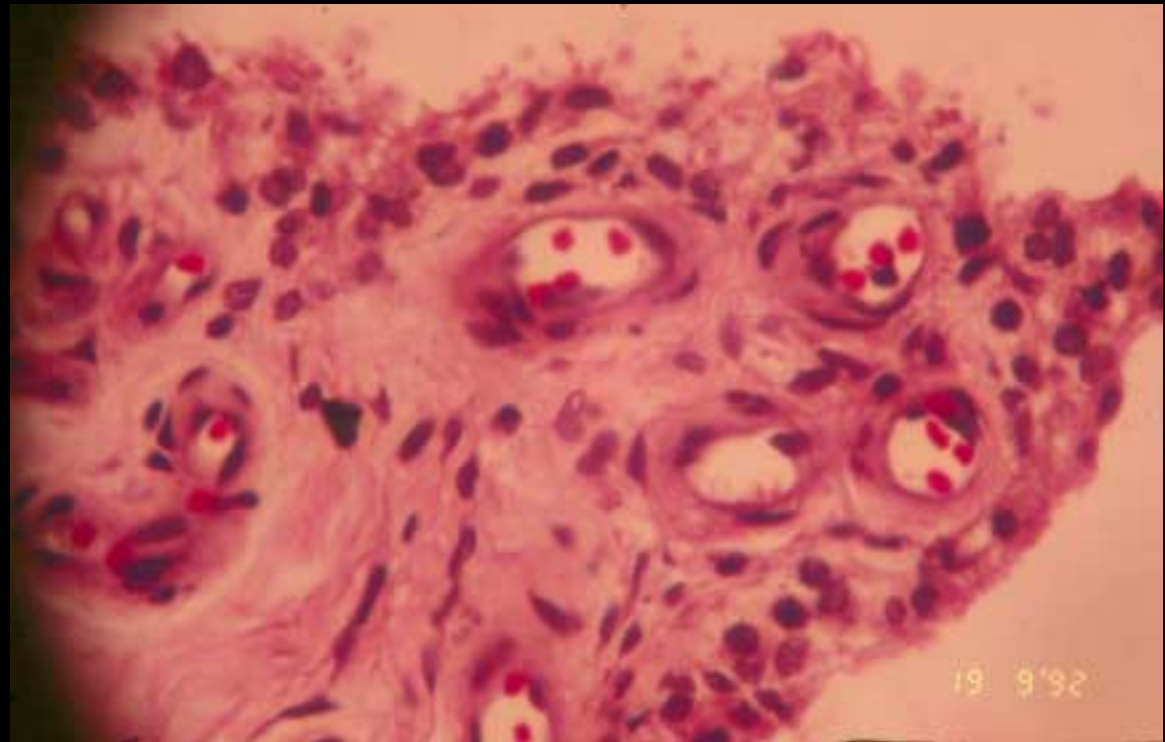
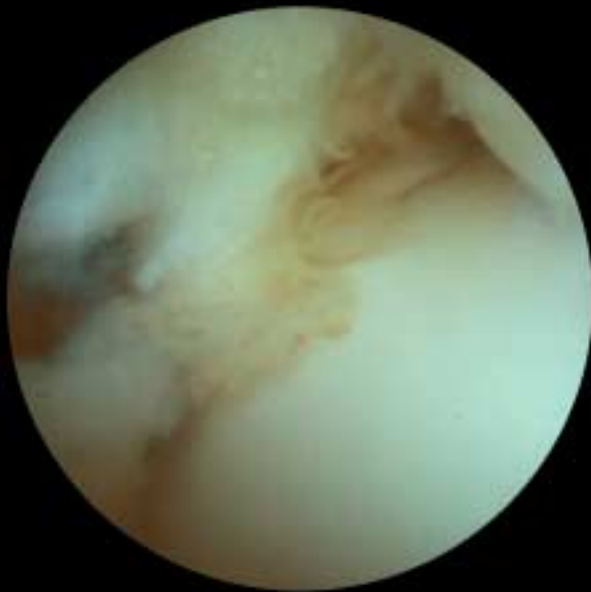
Ankle Arthroscopy

method

37 patients

Anterolateral soft tissue impingement

14

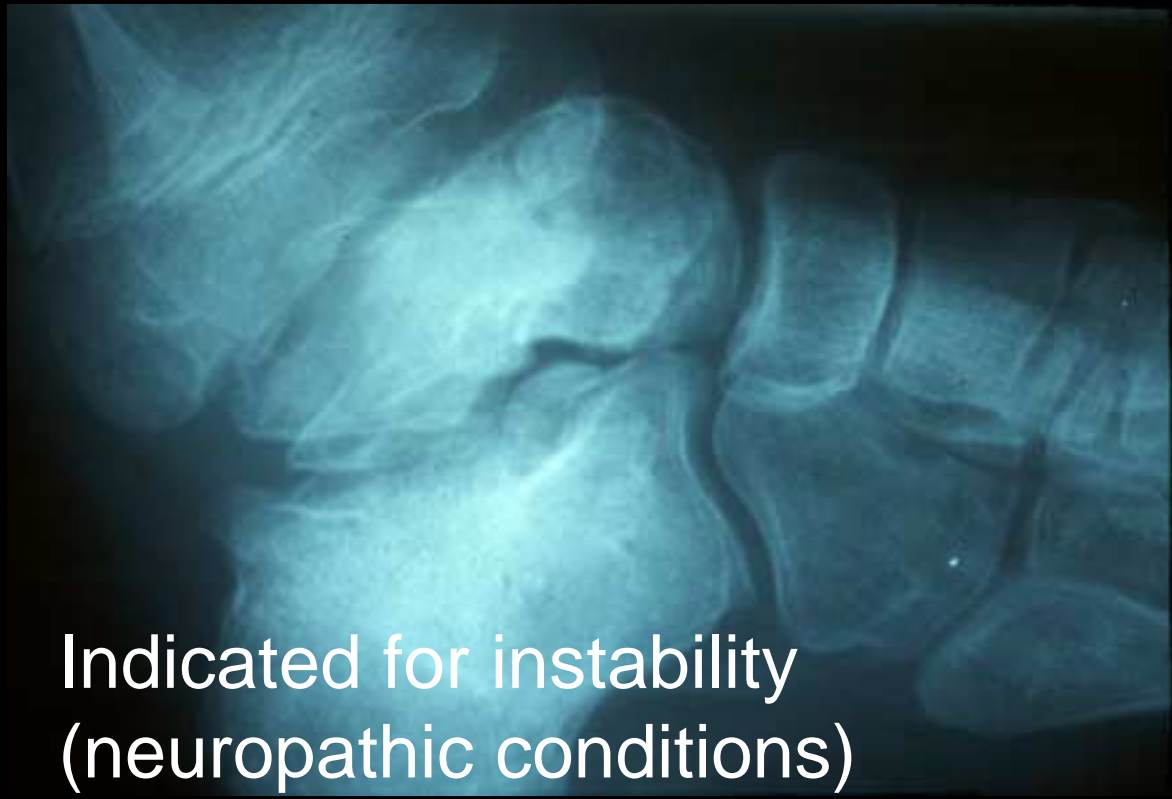
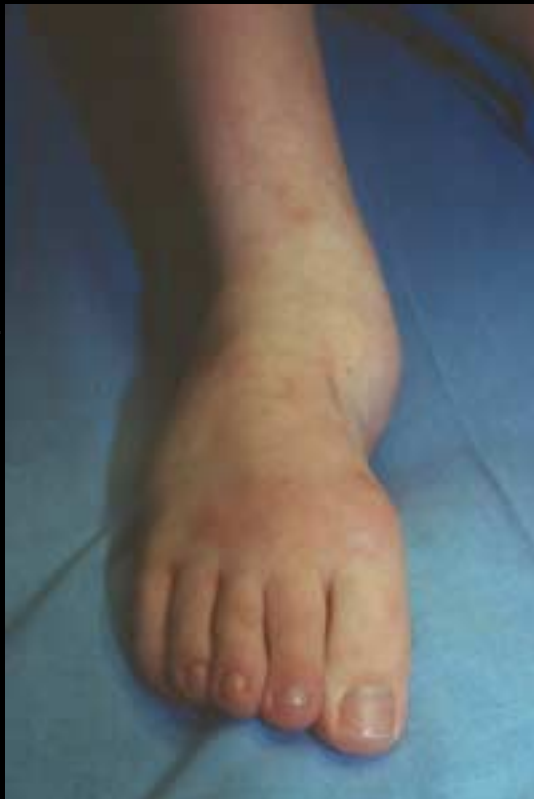
Ankle Arthroscopy

method

37 patients

Arthroscopic subtalar arthrodesis	1
-----------------------------------	---



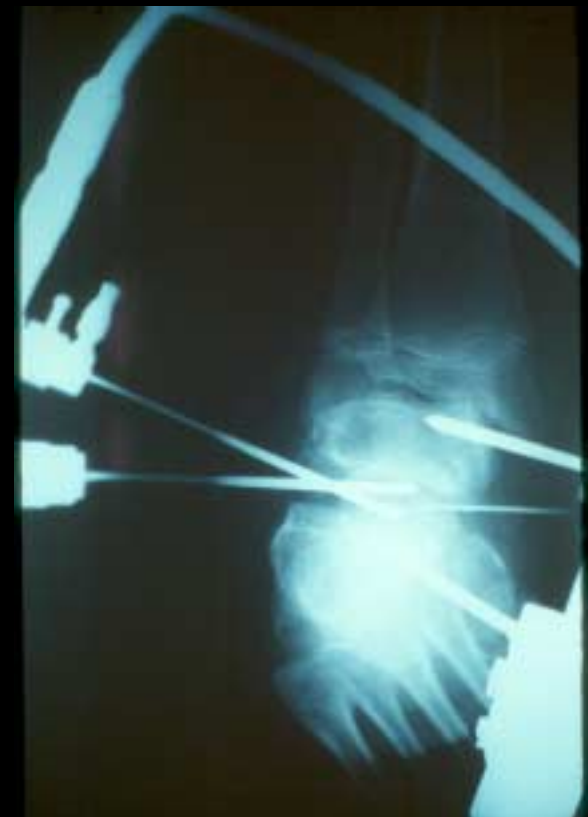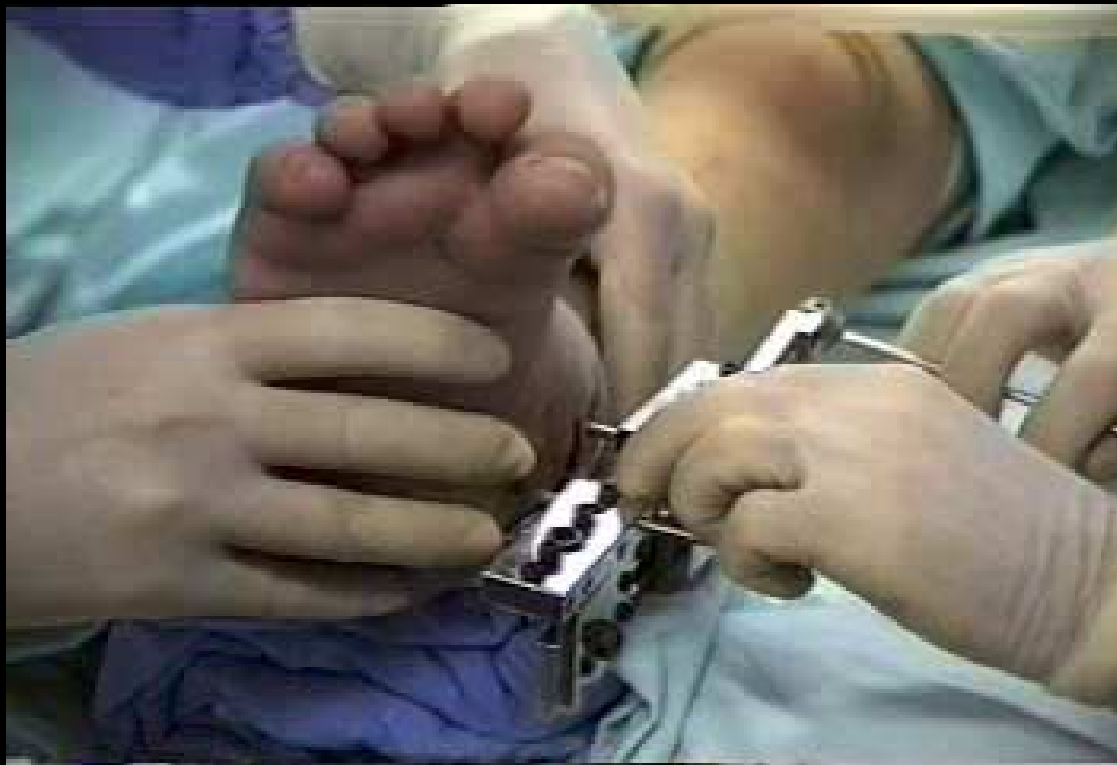Indicated for instability
(neuropathic conditions)

Ankle Arthroscopy

method

37 patients

Arthroscopic subtalar arthrodesis	1
-----------------------------------	---



Ankle Arthroscopy

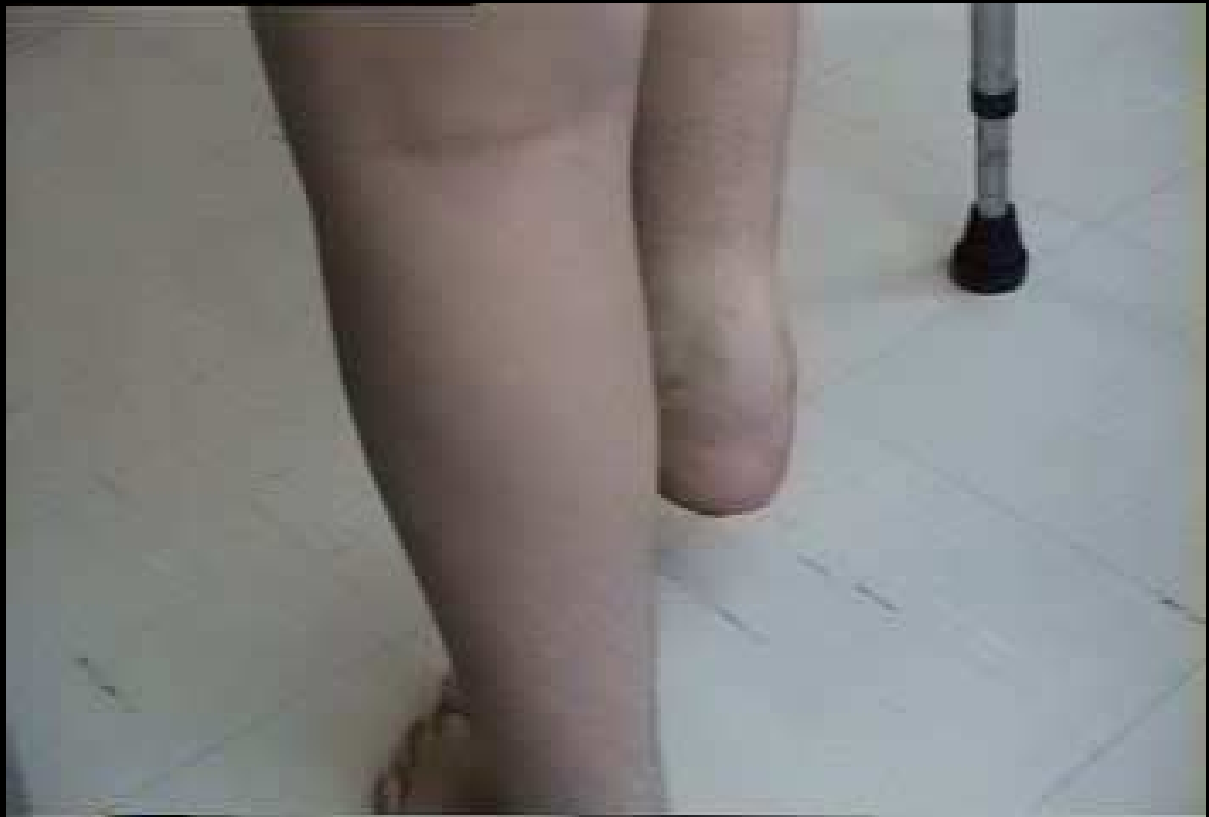method

37 patients

Arthroscopic subtalar arthrodesis	1
-----------------------------------	---

Pre

Post



Ankle Arthroscopy

results

37 patients

Improvement in: pain, swelling, stiffness,
activity and instability

Excellent	18	48%
Good	17	46%
Fair	1	3%
Poor	1	3%

Ankle Arthroscopy

results

37 patients

Improvement in: pain, swelling, stiffness,
activity and instability

- 36 patients benefited in some way from the procedure

- 1 patient with degenerative joint disease had the worst result